

Streptococcus Suis Meningitis: A Case Report from South India

Dr. Josekutty Mathew¹, Dr. Jose Kunnel², Dr. Geena George³, Dr. Ansu C Alex⁴

ABSTRACT

Streptococcus suis is a zoonotic pathogen predominantly associated with occupational or dietary exposure to pigs or pork products. While cases are frequently reported from Southeast Asia, reports from India remain scarce. This case report highlights the clinical presentation, diagnosis, and management of *S. suis* meningitis in an immunocompetent individual from South India.

ARTICLE DETAILS

Published On:
11 December 2024
Available on:
<https://ijmscr.org/>

CASE HISTORY

A 46-year-old gentleman presented with a one-week history of fever and low back pain, along with a one-day history of severe headache and tiredness. On examination, he was conscious but disoriented to time and place. His pupils were equal and reactive, and extraocular movements were intact and full. He was moving all four limbs, and bilateral plantar reflexes were flexor. However, neck stiffness was noted on examination.

An MRI with contrast was performed, which showed no significant abnormalities. However, given the clinical signs of meningitis, the patient was started on treatment with ceftriaxone 2g IV twice daily, along with vancomycin and acyclovir.

His total white blood cell count was initially elevated at 24,980, and C-reactive protein (CRP) was elevated at 193.6. Procalcitonin was also positive at 17.6, and sodium was low

at 131. A lumbar puncture was performed, revealing 1,750 cells, with 85% neutrophils and the presence of red blood cells. There was hypoglycorrhachia in the cerebrospinal fluid (CSF) with a CSF glucose level of 30.6 mg/dL (corresponding blood glucose of 110 mg/dL). CSF protein was elevated at 595.8 mg/dL. Gram stain showed gram-positive diplococci, and blood cultures initially grew *Streptococcus suis*, which was sensitive to the antibiotics being administered. CSF cultures also grew *Streptococcus suis*, sensitive to the same antibiotics. CSF GeneXpert and CSF BioFire panel were both negative.

Vancomycin and acyclovir were discontinued, and the patient's clinical condition gradually improved, with resolution of fever and occasional mild headache. He will continue ceftriaxone for a total of 14 days. The patient is being discharged in stable condition.

CSF

| Test | Result |
|-------------------------|------------------------------------|
| Total Cell Count | 1750 cells/ μ L |
| Differential Count | Neutrophils: 85%, Lymphocytes: 15% |
| Glucose | 30.6 mg/dL (Low) |
| Protein | 595.8 mg/dL (High) |
| Lactate | 14.7 mmol/L (High) |
| RBCs | Present |
| Gram Stain | Gram-positive cocci in pairs |
| Culture Result | <i>Streptococcus suis</i> |
| GeneXpert MTB/RIF Ultra | Not Detected |
| Biofire Panel | Negative |

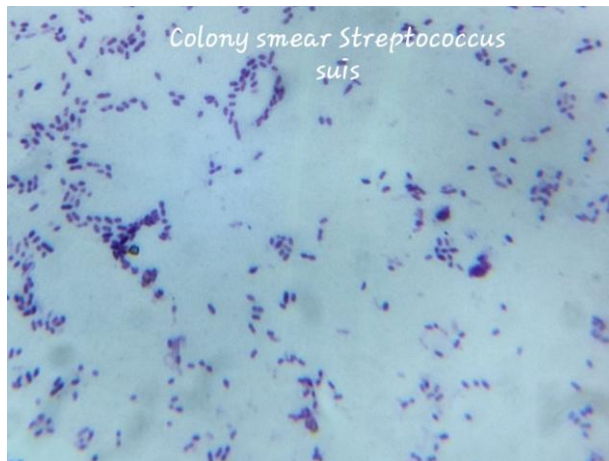
| WBC Count Progression Chart | | | | | |
|--------------------------------|-------|-------|-------|-------|-------|
| WBC Count (TLC x1000/ μ L) | D1 | D2 | D3 | D5 | D12 |
| Total WBC Count | 24.98 | 40.47 | 34.64 | 24.80 | 11.68 |
| Neutrophils (%) | 94.9 | 96.8 | 94.6 | 87.2 | 64.9 |
| Lymphocytes (%) | 94.9 | 96.8 | 94.6 | 87.2 | 64.9 |

Streptococcus Suis Meningitis: A Case Report from South India

| | | | | | | |
|-----------------|-----|-----|-----|-----|-----|------|
| Eosinophils (%) | 1.8 | 0.1 | 2.0 | 3.3 | 0.4 | 12.7 |
| Monocytes (%) | 0.5 | 1.4 | 1.4 | 2.5 | 4.2 | 3.4 |

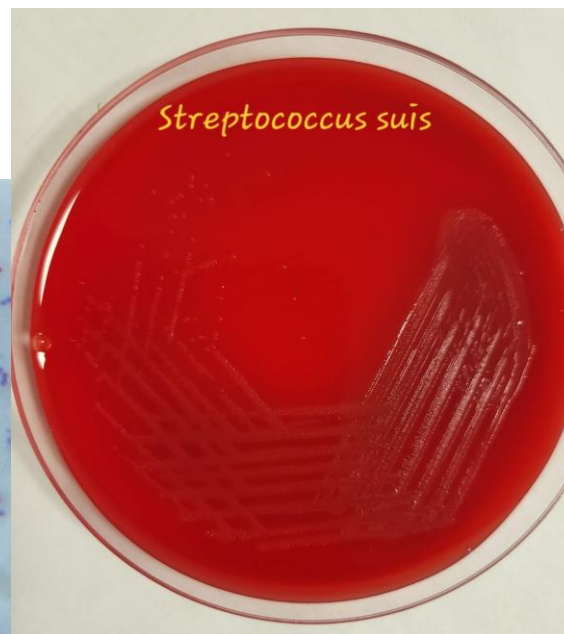
MICROBIOLOGICAL DIAGNOSIS

Streptococcus suis is a gram-positive cocci that appears in pairs. Streptococci are non-motile, gram-positive, catalase-negative coccoid bacteria that occur singly, in pairs, or in short chains when observed on stained smears. It can be



Gram stain

diagnosed using standard CSF and blood culture techniques. The usual BioFire panel does not include **Streptococcus suis**, so it may be missed during routine PCR assays. In our patient, it was isolated from both blood and CSF samples.



culture

DISCUSSION

Streptococcus suis is a zoonotic pathogen commonly found in pigs and can cause disease in humans through contact with contaminated pigs or pork products. It typically presents as acute meningitis but can also affect other sites, leading to conditions such as infective endocarditis, septic arthritis, and endophthalmitis. In Europe, *Streptococcus suis* is primarily recognized as an occupational disease linked to pig farming or handling raw pork. Most cases are reported from Southeast Asia, including countries like Vietnam, Thailand, and China. If not properly treated, *Streptococcus suis* can lead to meningitis with neurological sequelae. A meta-analysis showed a case fatality rate of 12%, with the most common neurological complications being hearing loss and vestibular dysfunction. (4)

From South India, to the best of our knowledge, only a few cases of *Streptococcus suis* infection have been reported, and this is our first case of bacterial meningitis diagnosed with *Streptococcus suis*.

There are case studies that show *Streptococcus suis* can cause infective endocarditis. In our case, this was ruled out. The duration of antibiotics was guided by the diagnosis of *Streptococcus suis* meningitis. A large prospective study suggests that a 2-week duration of antibiotics can lead to a cure in up to 97% of cases (1). However, some case reports suggest the possibility of recrudescence of *suis* meningitis (2). In these cases, it can present within one week after cessation of

antibiotic therapy, and may require a prolonged course of antibiotics for up to 6 weeks. In our case, a repeat CSF study was conducted before discharge, which showed no cells. Clinical case reporting is crucial for implementing preventive measures in pig farming, as *Streptococcus suis* infections are primarily associated with occupations related to pig farming, slaughtering, and the sale of pig products (5)

CONFLICT OF INTEREST STATEMENT/FUNDING

None to declare.

ETHICAL APPROVAL

Not applicable

REFERENCE

- I. Wertheim HF, Nghia HD, Taylor W, Schultsz C. *Streptococcus suis*: an emerging human pathogen. Clin Infect Dis 2009;48:617–25. Woo J, Li EK. *Streptococcus suis* meningitis requires prolonged treatment with penicillin. Infection 1987;15:129–30.
- II. Woo J, Li EK. *Streptococcus suis* meningitis requires prolonged treatment with penicillin. Infection 1987;15:129–30.
- III. Huong VT, Ha N, Huy NT, et al.: Epidemiology, clinical manifestations, and outcomes of *Streptococcus suis* infection in humans. Emerg Infect Dis. 2014, 20:110514.

Streptococcus Suis Meningitis: A Case Report from South India

10.3201/eid2007.131594

- IV. Gottschalk M, Segura M, Xu J. *Streptococcus suis* infections in humans: the Chinese experience and the situation in North America. *Anim Health Res Rev* **2007**; 8:29–45
- V. Agoston Z, Terhes G, Hannauer P, et al. Fatal case of bacteraemia caused by *Streptococcus suis* in a splenectomised man and a review of the European literature. *Acta Microbiol Immunol Hung*. 2020;67:148–55..