

## Longitudinal Transverse Myelitis in a Case of Systemic Lupus Erythematosus: A Clinical Analysis and Review of the Literature

Cynthia Mariella Portales Rivera<sup>1</sup>, María Teresa Canseco Franco<sup>2</sup>, José Emiliano González Flores<sup>3</sup>

<sup>1,2,3</sup> Escuela de Medicina y Ciencias de la Salud, Tecnológico de Monterrey, Campus Ciudad de México

### ABSTRACT

Systemic lupus erythematosus (SLE) is a chronic autoimmune disease characterized by a relapsing-remitting course and multisystem involvement, including the central nervous system (CNS). Neuropsychiatric manifestations in SLE vary widely and may include psychiatric disorders, seizures, cerebrovascular diseases, neuropathy, and cognitive dysfunction. Among the rare but severe complications is transverse myelitis (TM), an inflammatory disorder of the spinal cord that can cause motor, sensory, and autonomic dysfunction. In SLE, TM has an estimated incidence of 0.5% to 1%, with TM as the initial presentation in 30-60% of cases. The pathogenic mechanisms of SLE-related TM are complex, involving autoimmune responses with autoantibodies such as anti-dsDNA and antiphospholipid antibodies, which contribute to vascular damage and inflammation. A 59-year-old female with a history of SLE presented to the emergency department with lower limb sensory alterations, sudden loss of gait, and dysautonomia. Neurological examination revealed motor strength 0/5 in the lower limbs, areflexia, and hypotonia, with sensory level at T10. MRI findings indicated ischemic spinal infarction from T4 to T12, suggestive of longitudinally extensive TM. Given the absence of compressive pathology and infectious causes, high-dose corticosteroids and plasma exchange were initiated based on European League Against Rheumatism (EULAR) guidelines.

**KEYWORDS:** Systemic Lupus Erythematosus, Transverse Myelitis, Autoimmune complications, Immunosuppressive therapy

### ARTICLE DETAILS

**Published On:**  
**19 November 2024**

**Available on:**  
**<https://ijmscr.org/>**

### INTRODUCTION

Systemic lupus erythematosus (SLE) is a chronic autoimmune disease characterized by a relapsing-remitting course and multisystem involvement, including the central nervous system (CNS). Neuropsychiatric manifestations in SLE are diverse and may include psychiatric disorders, seizures, cerebrovascular diseases, neuropathy, and cognitive dysfunction. The prevalence of neuropsychiatric manifestations in SLE varies widely, reported between 14% and 75% in different studies, depending on the criteria and methods used for evaluation (1-3).

The pathogenesis of neuropsychiatric manifestations is complex and not fully understood, but it is believed to involve microangiopathy, the production of autoantibodies, and inflammatory cytokines (2,4). The American College of Rheumatology (ACR) has defined 19 neuropsychiatric syndromes associated with SLE, including primary manifestations directly related to SLE and secondary

manifestations due to other factors such as treatment or metabolic abnormalities (5).

Transverse myelitis (TM) is an inflammatory disorder of the spinal cord that can cause motor, sensory, and autonomic dysfunction. It is characterized by inflammation in one or more segments of the spinal cord, leading to symptoms such as limb weakness, sensory disturbances, and bladder or bowel dysfunction. TM can occur as an isolated condition or in association with systemic diseases, including systemic lupus erythematosus (SLE). In the context of SLE, transverse myelitis is a rare but serious complication, with an estimated incidence of 0.5% to 1% among SLE patients.<sup>6</sup> It may be the initial manifestation of SLE in a significant proportion of cases, ranging from 30% to 60% (6).

The causes of transverse myelitis in the context of SLE are multifactorial. Autoimmune processes are fundamental, involving autoantibodies such as anti-dsDNA and antiphospholipid antibodies, which may contribute to

## Longitudinal Transverse Myelitis in a Case of Systemic Lupus Erythematosus: A Clinical Analysis and Review of the Literature

vascular damage and inflammation in the spinal cord (7, 8). Other possible triggers include infections, which may precipitate or exacerbate autoimmune responses, and possibly environmental factors, though these are not well defined (9). Treatment of SLE-related transverse myelitis often involves high doses of corticosteroids and immunosuppressive therapies like cyclophosphamide, which have shown to improve outcomes in some patients (7, 10). However, due to the rarity of the condition, there are no standardized treatment protocols, and management is often based on clinical experience and case reports (6, 10).

### CASE PRESENTATION

A 59-year-old female patient presented to the emergency department with altered sensation in the lower limbs, sudden loss of gait, and a fall from her own standing height, resulting in a contusion on the left side of her face. Neurological examination showed 0/5 muscle strength in the lower limbs, areflexia, and hypotonia, with bilateral indifferent plantar response and a sensory level starting from T10.

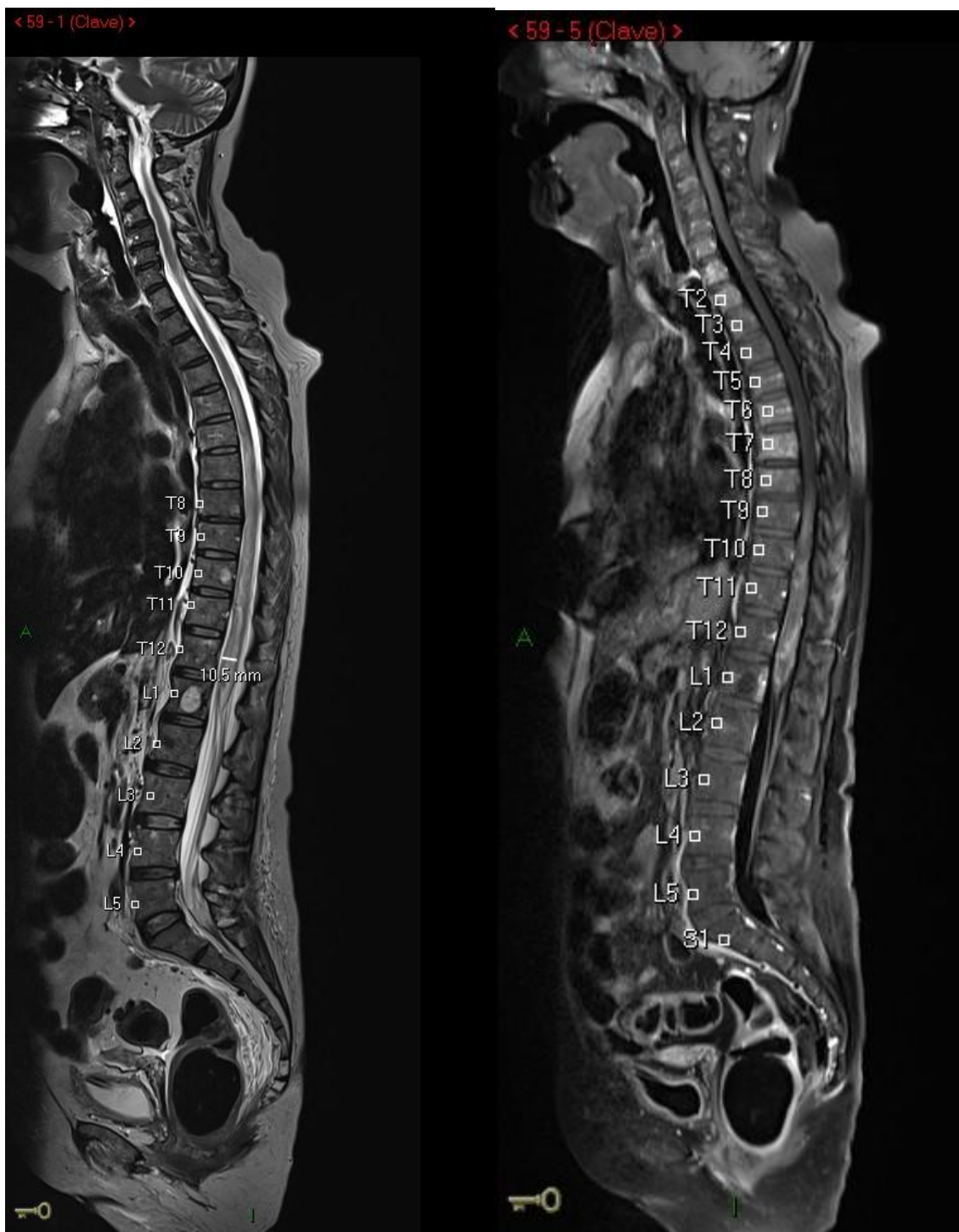
The patient was admitted to internal medicine for assessment and treatment. During her stay, a spinal MRI (**Image 1**) showed findings suggestive of spinal ischemia-infarction from T4 to T12 in the territory of the anterior spinal artery. In the absence of compressive disease, findings were compatible with longitudinally extensive transverse myelitis, ruling out an inflammatory-infectious process. A lumbar puncture with a multiplex PCR meningitis panel was performed, yielding a negative result, thus no conclusive infectious cause was identified.

The patient had a history of systemic lupus erythematosus (SLE) diagnosed in 2012, with hematological activity (thrombocytopenia), pleuritis, and renal involvement, but no cutaneous, mucosal, or joint activity. She had been treated with mycophenolate mofetil, which was discontinued in 2018 due to apparent remission of the disease. Given her

underlying rheumatological disease and high immunological probability, a rheumatological panel was requested, and pulses of methylprednisolone were started. However, due to the severity of her spinal condition and progression of sensory symptoms, a Mahurkar catheter was placed, and plasmapheresis was initiated. Subsequently, she developed dysautonomia, presenting with hypotension (BP 90/50 mmHg), a mean arterial pressure of 63 mmHg, and an oscillating heart rate of 50 to 60 bpm, with a tendency toward bradycardia, leading to her admission to intermediate care for hemodynamic monitoring, where steroid and plasmapheresis treatment continued.

Her relevant family and medical history included a sister with SLE and another sister with rheumatoid arthritis. Additionally, the patient had a history of chronic diarrhea treated with pancreatin and simethicone. Tests ruled out celiac disease or other abnormalities.

In 2023, she had recurrent episodes of urinary incontinence and urinary tract infections, leading to cystoscopy, intravesical Botox placement, and medical treatment with darifenacin 7.5 mg every 24 hours. In the first half of 2024, she continued to experience urinary tract infections due to multidrug-resistant bacteria, along with a grade IV pressure ulcer in the sacral region, which was difficult to manage. She required intermittent urinary catheterization and continuous diaper use due to severe fecal incontinence, prompting a referral to general surgery for permanent colostomy. During her preoperative assessment, complete bowel preparation and preoperative colonoscopy were performed without significant findings. Enterostomal therapy marked the stoma site. She was scheduled for a terminal colostomy with an extraperitoneal technique by laparoscopy. The patient had an adequate recovery, with progressive tolerance to oral intake and appropriate colostomy output and was discharged on her second postoperative day.



**Image 1. Magnetic Resonance Imaging (MRI).** Increased hyperintensity in the T2 and STIR sequences of the spinal cord. Currently extending from T2 to the topography of the conus medullaris at the level of L1 in the axial plane, this hyperintensity involves the ventral and central components, with persistent molecular restriction in this hyperintense area showing low apparent diffusion coefficient (ADC) levels. There is also widening of the medullary diameter, with a maximum thickness of 10 mm at T12. In the gradient echo sequence, there is laminar hypointensity running through the central canal from T10 to the conus medullaris, suggestive of hemosiderin remnants. After contrast administration, heterogeneous enhancement of the affected area is observed. The roots of the cauda equina still retain their signal, with normal thickness. The cervical segment shows no alterations, only a slight increase in the width of the ependymal canal.

#### DISCUSSION

The diagnosis of transverse myelitis (TM) is based on specific findings in the clinical history, physical examination, and

imaging studies. Clinical findings include symptoms compatible with myelopathy, such as the abrupt onset of weakness and sensory loss in a myelopathic distribution, as

## Longitudinal Transverse Myelitis in a Case of Systemic Lupus Erythematosus: A Clinical Analysis and Review of the Literature

well as bowel or bladder incontinence and urinary retention (11). In the described case, physical examination showed sudden gait loss, altered sensation in the lower limbs with 0/5 muscle strength, areflexia, hypotonia, bilateral indifferent plantar response, and sensory level starting from T10. Additionally, autonomic symptoms manifested as urinary incontinence and chronic diarrhea, requiring both surgical and pharmacological management.

Imaging findings for TM are typically obtained through gadolinium-enhanced MRI of the spine, the diagnostic study of choice for suspected transverse myelitis. MRI typically shows a signal anomaly that enhances with gadolinium in the spinal cord, with lesions extending across three or more vertebral segments (11), giving it the name longitudinally extensive transverse myelitis (LETM). The MRI performed on the patient showed findings suggestive of spinal ischemia-infarction from T4 to T12 in the anterior spinal artery territory, with no compressive pathology that could explain the patient's clinical symptoms.

The patient also had a history of systemic lupus erythematosus (SLE) diagnosed and treated over six years (2012–2018), with treatment discontinuation from 2018 to 2024. As previously explained, the etiology of TM is uncertain; however, it is known to occur in the context of ongoing neuroinflammatory disorders. Various theories have been proposed, including blood-brain barrier dysfunction, antibody-mediated mechanisms, and vascular causes, as vasculitis, venous hypertension (due to spinal inflammation), and thrombosis are believed to contribute to ischemia and spinal cord myelitis (14). Neuroinflammatory causes include central nervous system demyelinating diseases such as neuromyelitis optica, systemic autoimmune inflammatory disorders like SLE, followed by paraneoplastic syndromes and infectious causes (11), which were ruled out due to a negative lumbar puncture with a meningitis panel and the absence of additional significant findings beyond those mentioned in imaging studies. SLE-related TM is an unusual but severe complication, occurring in approximately 1-2% of patients but potentially affecting up to 30-60% (14). Similar to SLE, TM (associated with this disease) predominantly affects women (14). Moreover, a family history of rheumatic diseases, as seen in this patient with two first-degree relatives affected, confers a higher risk for more diverse clinical courses (15).

Based on the results obtained, TM was confirmed. Given the suspicion of acute autoimmune inflammatory myelitis, pulses of methylprednisolone were initiated. According to the European League Against Rheumatism (EULAR), in cases of myelitis within an autoimmune context, acute treatment consists of high-dose glucocorticoid pulses followed by a gradual reduction of oral steroids, often combined with intravenous cyclophosphamide (13, 15). Studies have shown better outcomes in patients who began treatment within two weeks of symptom onset (15). In severe cases or those not

responding to initial immunosuppression therapy, simultaneous plasma exchange, intravenous immunoglobulin, or rituximab therapy may be administered (13, 15). Chronic treatment consists of continuing cyclophosphamide for three to six months, later substituting it with a less toxic agent for maintenance therapy to control disease activity and reduce the risk of recurrence (13, 15).

Subsequent studies demonstrated that the use of mycophenolate mofetil and azathioprine leads to better outcomes, while hydroxychloroquine reduces neurological flares (15).

However, due to the findings described in imaging studies, an important differential diagnosis to consider is vascular myelopathy. Among vascular conditions presenting acutely (within hours) in this case is spinal cord infarction, particularly in the anterior spinal artery. The clinical presentation is like that described: acute or subacute paraparesis or quadriparesis, sensory alterations localized to a spinal level, and bowel or bladder dysfunction. Although imaging studies are indispensable for diagnosis, they may mimic multiple etiological entities. MRI shows focal spinal cord inflammation, hyperintensity in T2-weighted images and STIR sequence, restricted diffusion in diffusion-weighted images (DWI), and enhancement in post-contrast images (12). In the context of SLE-associated TM, MRI shows T2 hyperintensity in the affected spinal cord area and, in acute contexts, gadolinium-enhanced contrast (13). More specific findings for spinal infarction include vertebral body infarction adjacent to spinal cord signal anomalies on MRI and T2 hyperintensity or restricted diffusion in a spinal vascular territory or ventral horns (the “owl’s eyes” or “snake eyes” sign) (12). This highlights the importance of correlating imaging findings with clinical characteristics and considering additional studies (such as serum aquaporin-4, NMO IgG antibodies, or cerebrospinal fluid tests) (16) since treatment differs significantly. Unlike TM caused by SLE, vascular myelopathy management focuses on maneuvers to restore spinal cord perfusion (12).

### CONCLUSIONS

Transverse myelitis is a severe and rare neurological condition characterized by motor, sensory, and autonomic dysfunction. In the presented case, the 59-year-old female patient with a history of systemic lupus erythematosus (SLE) diagnosed in 2012 developed acute symptoms such as gait loss, altered sensation in the lower limbs, and dysautonomia, manifesting as hypotension and bradycardia.

The diagnosis of TM in this patient was based on a careful clinical evaluation, MRI findings showing spinal ischemia-infarction from T4 to T12, and the exclusion of infectious causes through a negative lumbar puncture for meningitis. The patient’s management included initiating methylprednisolone pulses and plasmapheresis, following the

## Longitudinal Transverse Myelitis in a Case of Systemic Lupus Erythematosus: A Clinical Analysis and Review of the Literature

European League Against Rheumatism (EULAR) recommendations for acute treatment of myelitis in the context of autoimmune diseases. These treatments aim to reduce inflammation and disease activity, with their efficacy being greater when initiated within the first two weeks of symptom onset (13, 15).

SLE-associated TM, although rare, is a serious complication that requires specialized attention and treatment to improve the patient's quality of life and minimize the impact of this debilitating condition.

### REFERENCES

- I. Postal, M., Costallat, L. T., & Appenzeller, S. (2011). Neuropsychiatric manifestations in systemic lupus erythematosus: epidemiology, pathophysiology and management. *CNS drugs*, 25(9), 721–736. <https://doi.org/10.2165/11591670-000000000-00000>
- II. Hanly J. G. (2001). Neuropsychiatric lupus. *Current rheumatology reports*, 3(3), 205–212. <https://doi.org/10.1007/s11926-001-0020-7>
- III. Meier, A. L., Bodmer, N. S., Wirth, C., Bachmann, L. M., Ribl, C., Pröbstel, A. K., Waerber, D., Jelcic, I., Steiner, U. C., & Swiss SLE Cohort Study (SSCS) (2021). Neuro-psychiatric manifestations in patients with systemic lupus erythematosus: A systematic review and results from the Swiss lupus cohort study. *Lupus*, 30(10), 1565–1576. <https://doi.org/10.1177/09612033211025636>
- IV. Jeltsch-David, H., & Muller, S. (2014). Neuropsychiatric systemic lupus erythematosus: pathogenesis and biomarkers. *Nature reviews. Neurology*, 10(10), 579–596. <https://doi.org/10.1038/nrneuro.2014.148>
- V. Hanly J. G. (2014). Diagnosis and management of neuropsychiatric SLE. *Nature reviews. Rheumatology*, 10(6), 338–347. <https://doi.org/10.1038/nrrheum.2014.15>
- VI. Jain, S., Khormi, A., Sangle, S. R., & D'Cruz, D. P. (2023). Transverse myelitis associated with systemic lupus erythematosus (SLE-TM): A review article. *Lupus*, 32(9), 1033–1042. <https://doi.org/10.1177/09612033231185612>
- VII. Kovacs, B., Lafferty, T. L., Brent, L. H., & DeHoratius, R. J. (2000). Transverse myelopathy in systemic lupus erythematosus: an analysis of 14 cases and review of the literature. *Annals of the rheumatic diseases*, 59(2), 120–124. <https://doi.org/10.1136/ard.59.2.120>
- VIII. Calleja, J., Ceballos-Ceballos, J., Treviño-Frenk, I., González-Duarte, A., Dávila-Maldonado, L., Cantú-Brito, C., & Valdés-Ferrer, S. I. (2018). Natural history of longitudinally extensive transverse myelitis in 35 Hispanic patients with systemic lupus erythematosus: good short-term functional outcome and paradoxical increase in long-term mortality. *Lupus*, 27(8), 1279–1286. <https://doi.org/10.1177/0961203318770015>
- IX. Bhat, A., Naguwa, S., Cheema, G., & Gershwin, M. E. (2010). The epidemiology of transverse myelitis. *Autoimmunity reviews*, 9(5), A395–A399. <https://doi.org/10.1016/j.autrev.2009.12.007>
- X. Wen, X., Xu, D., Yuan, S., & Zhang, J. (2022). Transverse myelitis in systemic lupus erythematosus: A case report and systematic literature review. *Autoimmunity reviews*, 21(6), 103103. <https://doi.org/10.1016/j.autrev.2022.103103>
- XI. Greenberg, B. (2024). Transverse myelitis: etiology, clinical features, and diagnosis. *UpToDate*.
- XII. Mullen, M. & McGarvey, M. (Mayo 21, 2024). Spinal cord infarction: Clinical presentation and diagnosis. *UpToDate*.
- XIII. Gelfand, J. & Yazdany, J. (Marzo 07, 2024). Neurologic and neuropsychiatric manifestations of systemic lupus erythematosus. *UpToDate*.
- XIV. Jain, S., Khormi, A., Sangle, S. R., & D'Cruz, D.,P. (2023). Transverse myelitis associated with systemic lupus erythematosus (SLE-TM): A review article. *Lupus*, 32(9), 1033–1042. <https://doi.org/10.1177/09612033231185612>
- XV. Kwon, Y., Ha, E., Kwon, H., Park, D. J., Shin, J., Joo, Y. B., Chung, W. T., Yoo, D., Lee, H., Kim, K., Bae, S., & Bang, S. (2023). Higher Genetic Risk Loads Confer More Diverse Manifestations and Higher Risk of Lupus Nephritis in Systemic Lupus Erythematosus. *Arthritis & Rheumatology (Hoboken, N.J.)*, 75(9), 1566–1572. <https://doi.org/10.1002/art.42516>
- XVI. Mullen, M. & McGarvey, M. (Mayo 21, 2024). Spinal cord infarction: Treatment and prognosis. *UpToDate*.