

Emergency Management of Multiple Maxillofacial Trauma Patients with Head Injury: A Case Report

Ayu Vidya Putri¹, Endang Sjamsudin², Melita Sylviana³

¹Resident of Oral and Maxillofacial Surgery, Faculty of Dentistry, Universitas Padjadjaran/ RSUP Dr. Hasan Sadikin, Bandung, Indonesia

^{2,3}Department of Oral and Maxillofacial Surgery, Faculty of Dentistry, Universitas Padjadjaran/ RSUP Dr. Hasan Sadikin, Bandung, Indonesia

ABSTRACT

Trauma to the face has the potential to be life-threatening and cause facial deformities. Head injuries are usually a more severe consequence of such incidents and must be addressed earlier. Here we present a case of a 24-year old male patient with history fell from motorcycle three hours before the patient was admitted to the hospital, the patient fell with the mechanism of his face hitting the asphalt first. He was diagnosed with panfacial fracture of facial bones and mild head injury. Emergency treatment need to be done for his general condition improvement, transfusion of red blood cell, admister of electroltye, oxygenation and observation of consciousness, primary suture of laceration, placing erich bar wire for maxilla mandible, placing skin traction was done in the emergency room. The patient then was scheduled for open reduction internal fixation of the facial fracture after the condition was optimal enough. Maintaining the airway and limiting bleeding are fundamental concepts in the emergency department's management of maxillofacial trauma.

KEYWORD: Emergency Management, Maxillofacial Trauma, Head Injury, open reduction

ARTICLE DETAILS

Published On:
19 October 2023

Available on:
<https://ijmscr.org/>

Injuries considerably burden all populations worldwide, leading to high morbidity or mortality. Maxillofacial fracture is the most common injury worldwide. From 1990 to 2017, cases of maxillofacial fractures experienced an increase in incidence globally from 5,405,814 cases to 7,538,663 cases, an increase of 39.45%. Approximately 25% of all injuries reported in the National Trauma Data Bank involve fractures of the maxillofacial bone. This trauma may be due to its central location and anatomical factors resulting from damage to the middle facial bones. Trauma to the face has the potential to be life-threatening and cause facial deformities. Motor vehicle accidents and acts of violence are the leading causes of maxillofacial fractures.^{1,2,3,4}

Maxillofacial injuries may be limited to superficial lacerations and facial injuries and may also be associated with some head, chest, abdomen, cervical spine, or extremities injuries.⁴ Head injuries are usually a more severe consequence of such incidents and must be addressed earlier. The risk of head injury increases as the number of maxillofacial fractures increases and the level of consciousness decreases, which can be assessed with the

Glasgow Coma Scale (GCS). The prevalence of head injuries is 7.6% to 8.9% in cases of maxillofacial trauma.^{4,5}

The effects of this condition range from severe functional and aesthetic issues to life-threatening conditions. To rule out an underlying brain injury and lower mortality, every patient with a craniofacial fracture should have a detailed clinical and radiographic evaluation. Maxillofacial injuries can include deep lacerations, facial injuries, and some injuries to the head, chest, abdomen, cervical spine, or limbs. They can also be limited to superficial lacerations.⁴ Head injuries are typically a more significant result of such occurrences that require immediate attention. The Glasgow Coma Scale (GCS) can be used to measure the state of consciousness, and as the number of maxillofacial fractures rises, so does the risk of brain damage and the likelihood of a brain injury.⁵

Every patient with a maxillofacial injury, regardless of whether related to a fracture, is always at risk of experiencing a traumatic brain injury (TBI). We must be able to suspect and diagnose head injuries and provide adequate initial management. In addition, all patients with

Emergency Management of Multiple Maxillofacial Trauma Patients with Head Injury: A Case Report

maxillofacial injuries should undergo neurosurgical observation and follow-up. Rapid diagnosis and early intervention are crucial for preventing morbidity and mortality, especially those related to preventing traumatic brain injury (TBI), because hypoxia and edema in a short time will cause significant permanent neurological deficits. Multiple maxillofacial traumas accompanied by head injuries to prevent further complications and morbidity.^{6,7}

This case report represents an emergency management for the maxillofacial trauma patient involving a head injury. We need to make an early diagnose and treatment planning to avoid this condition becomes more life threatening and make a better prognosis.

CASE REPORT

It was reported that a 24-year-old male patient came to the emergency room at Hasan Sadikin Hospital Bandung complaining of bleeding in the mouth, asymmetrical face with hematoma at bilateral orbital region. Three hours before the patient was admitted to the hospital, the patient fell with the mechanism of his face hitting the asphalt first while riding a motorbike at moderate speed in the Cikalong area. The patient lost his balance at that time, and then his motorcycle hit a box car. The patient was taken to the Cikalong Hospital, and wound debridement, blood lab tests, and head and foot X-rays were carried out. The patient was then referred to the RSHS Emergency Room for further treatment. Patient history of helmet use (-), history of fainting (-), history of nausea and

vomiting (+), history of bleeding from the mouth (+), history of bleeding from the nose (+), bleeding from the ear (-), history of systemic disease (-), and a history of alcohol intoxication (-).

Initial assessment (primary survey) of the patient found: A: clear with C-spine control; B: symmetrical chest shape and movement; right Vesicular Breath Sound equal to left, respirations 23 times per minute; C: blood pressure 120/90 mmHg, pulse 93 times per minute, and D: assessment of head injury classification with the Glasgow Coma Scale GCS15 (E4M6V5) mild head injury. The patient's pupils had a round isochor diameter of 3 mm, left equal to right; no light reflex disturbances or paresis were found. The secondary survey found an abrasion wound with edema and bone discontinuity in the left leg region. General examination found positive skin turgor, an asymmetrical facial head, bilateral periorbital edema, and hematoma, left zygoma edema, and a left periorbital laceration with a size of 2x1x1 cm and irregular edges with a muscle base. The wound on the nasolabial area with irregular edges and muscle borders measuring 3x1x1 cm; the wound on the upper lip with 1x1x1 cm irregular edges on the base of the muscles (figure 1). The conjunctiva is not anemic, and the sclera is not icteric. Jugular vein pressure not increased, submandibular lymph nodes not palpable and painless, chest shape and motion symmetrical, no crackles and whistling found, regular pure heart sounds, a soft flat abdomen, normal positive bowel sounds, warm extremities, and capillary refill time less than 2 seconds.,

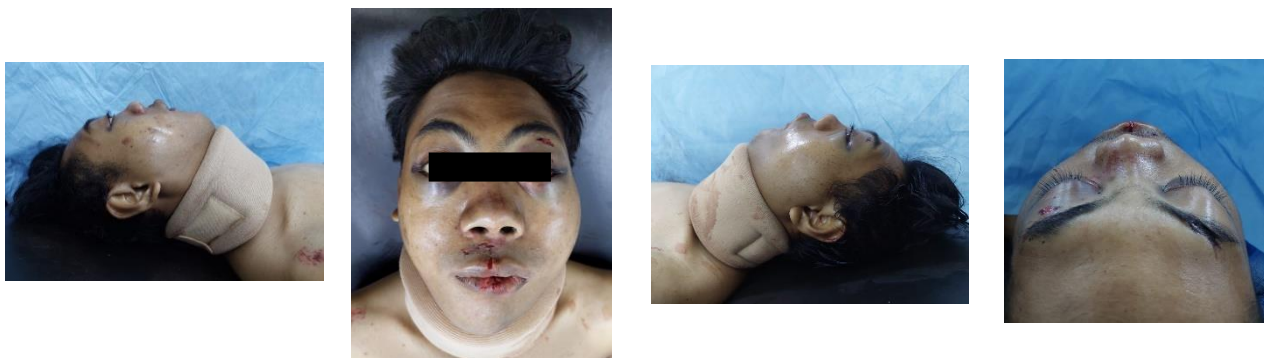

Figure 1. Clinical profile of the patient

In Figure 2, there is an intra-oral assessment, found avulsion of teeth 11,21 and fracture of 1/3 crown of tooth 12 accompanied by laceration of the gingiva of teeth 12-21, Dentoalveolar fracture of teeth 32, 41-43 accompanied by

gingival lacerations 32-43. Palatal fractures were also found to make holes in the palate accompanied by lacerations measuring 4x3x2 cm. Features of malocclusion with an open bite were also found in this patient.

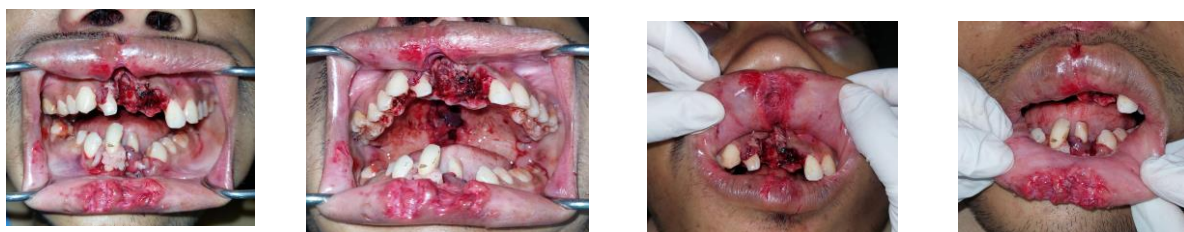

Figure 2. Intra-oral examination found lacerations, fractures and open bite malocclusion

Emergency Management of Multiple Maxillofacial Trauma Patients with Head Injury: A Case Report

Complete blood count and blood clotting factors obtained with results; Hb: 5.7 g/dL, PT: 15.70 seconds; INR: 0.93 seconds; APTT: 23.7 seconds; Hb: 15 g/dL; Htt45%; Leukocytes: 16,300/mm³; Erythrocytes: 1.91 million/uL; Platelets: 213,000/mm³; SGOT: 65 u/L, SGPT: 44 u/L, Timely blood glucose: 163 mg/dL, Sodium (Na): 136 mEq/L, Potassium (K): 4.0 mEq/L, Ureum: 48.5 mg/dL, Creatinine: 1.53 mg/dL. Anemia was found with a decrease in hemoglobin value of 5.7 g/dL accompanied by a decrease in hematocrit, leukocytosis, an increase in the value of

Prothrombin Time, INR, a decrease in the value of Ureum, and Creatinine.

The results of the X-ray examination of the chest, Cervical, and Pelvis found no abnormalities, whereas the X-ray of the femur found discontinuity in the dextra femur (Figure 3). 3D CT scan findings found discontinuities of the facial bones on bilateral frontonasal bones and frontozygoma, bilateral orbital bones of the median and inferior aspects of the rim, left zygoma, nasal bones, maxillary bones, mandibular symphysis bones (figure 4)

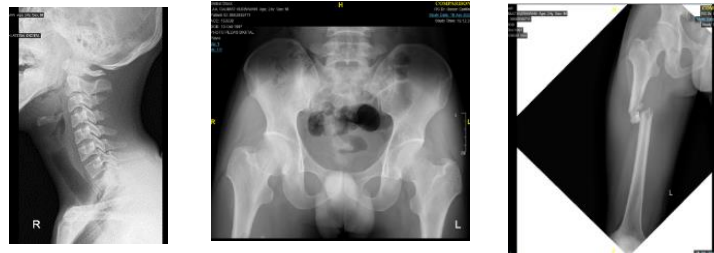

Figure 3. Examination of trauma series in cases of multiple trauma

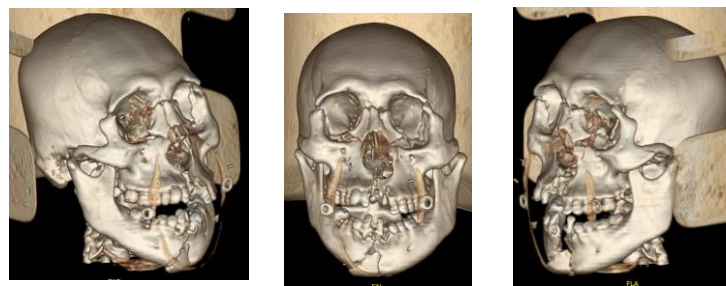


Figure 4. 3D CT scan in a patient in the RSHS emergency room showing multiple facial bone fractures

The physical examination and radiography results diagnosed this patient with multiple maxillofacial fractures accompanied by a mild head injury and femoral fractures. The treatment plan is a joint effort of the neurosurgery and orthopedic surgery departments after giving an explanation to the patient's family, getting approval for medical action, and getting approval if it is used for scientific publication. Emergency measures taken from the neurosurgery department are observation of the patient's consciousness with GCS assessment and vital signs; the patient's head position is 30 degrees; oxygenation with a nasal cannula of 2-4 liters per minute; an infusion of 0.9% NaCl of 1500 cc per day; and non-operative conservative treatment. While emergency measures from the Orthopedic Surgery department include giving 2 PRC transfusions to Hb above 10, using skin traction on the right leg, and preparing to do closed reduction and external reduction.

Emergency treatment in the Oral and Maxillofacial Surgery department is an injection of anti-tetanus serum (ATS) and tetanus toxoid (TT), 1 gram of Ceftriaxone antibiotics, 30 milligrams of Ketorolac analgesic, and an H2 blocker in the form of 50 milligrams of Ranitidine. Wound cleaning was carried out using 0.9% NaCl mixed with Gentamicin, with a ratio of 500 cc of 0.9% NaCl mixed with Gentamicin 2 cc (10 mg/cc). Alveolectomy in tooth regions 11, 21, and 32-42: Intraoral lacerations were sutured using silk 4.0, and extraoral lacerations were sutured using nylon 6.0 under local anesthesia. Temporary fixation was carried out using the Inter Dental Wiring (IDW) Erich Bar on the lower jaw of teeth 36-46 and maxilla 16-46, as well as the installation of intermolar wiring. The patient was planned to undergo open reduction internal fixation (ORIF) electively after 14 days after the accident traffic to be stable after the first head trauma.

Emergency Management of Multiple Maxillofacial Trauma Patients with Head Injury: A Case Report

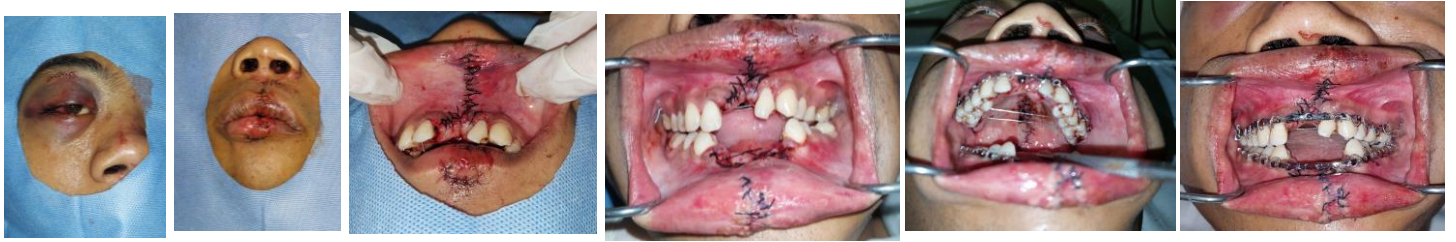

Figure 5. Post Operative Emergency Treatment

Seven days after the emergency procedure, the patient underwent suture opening in the extra oral and intra-oral areas, the wound was closed quite well, but the intermolar and interdental wiring of the upper and lower jaws was still

maintained. The wound in the palate region has not been completely closed, and Hyaluronic Acid gel is still being administered to the area. Patients are still instructed to consume a liquid diet.

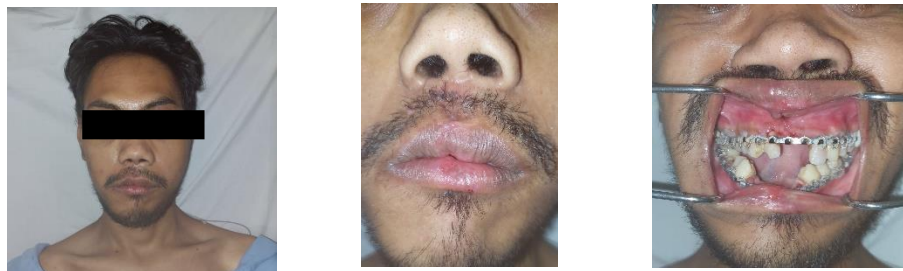

Figure 6. Post-Emergency Procedures for inserting interdental wires, intermolar wires and suturing the wound on the 7th day

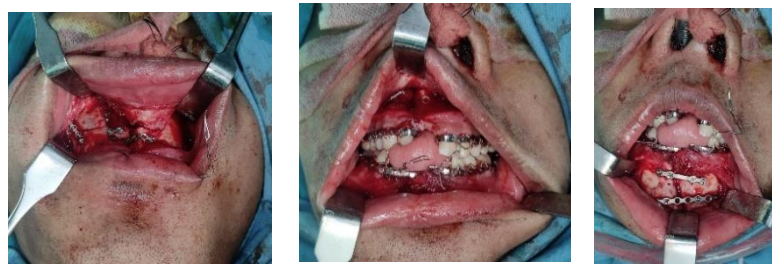

Figure 7. ORIF was performed by placing a plate on the maxillary and mandibular fracture

After 14 days of trauma, the patient continued definitive treatment for fractures of the facial bones, namely open reduction internal fixation using plates and screws placed on the fracture line. First, a plate was placed on the mandible, and occlusion adjustments were made. After the fracture fragment and stable occlusion, a plate and screw were placed on the maxilla using an L plate and straight with a diameter of 1.6, and then the occlusion was adjusted and achieved.

On the first postoperative day, MMF rubber was placed to maintain occlusion and prevent relapse. Patients are still being educated on a liquid diet for up to 3 weeks

postoperatively and instructions for maintaining dental and oral hygiene. The patient then continued outpatient treatment to evaluate the postoperative condition. Patients routinely control themselves every week. The control results obtained complaints of pain that began to decrease and swelling that began to decrease, indicating improvement. Condition one month postoperatively, an assessment was carried out through panoramic photos, and it was found that the condition of the plate was still in its proper position and postoperative bone healing (figure 8).

Emergency Management of Multiple Maxillofacial Trauma Patients with Head Injury: A Case Report

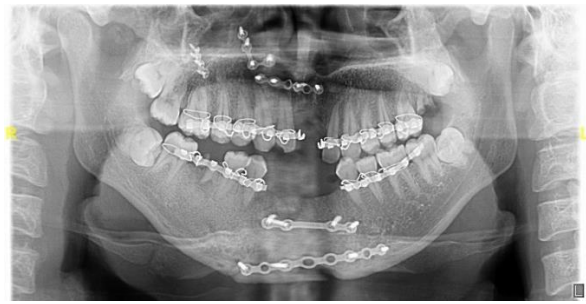

Figure 8. Post ORIF 1 month panoramic photo

On the 40 days postoperatively, control was carried out again and a better clinical condition was obtained; the occlusion was stable, complaints of no longer feeling surgical pain had disappeared, swelling had also disappeared, and removal of the interdental wiring was performed on the maxilla (figure 9).

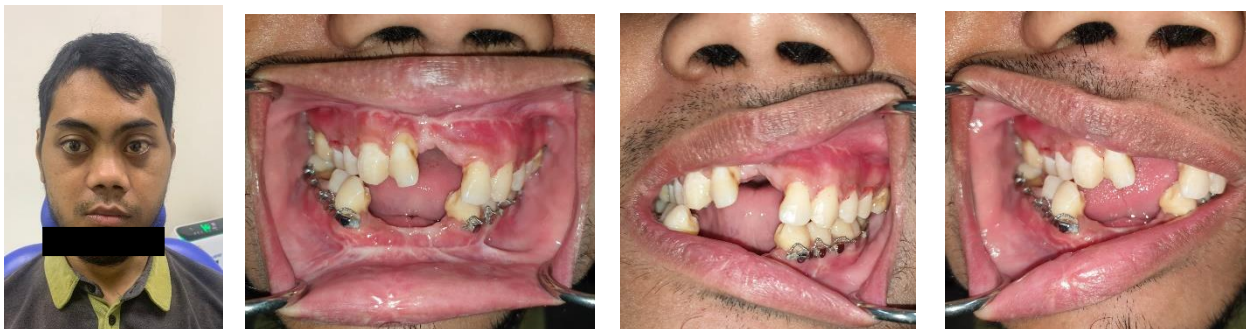

Figure 9. Postoperative control on the day 40

DISCUSSION

The human face is the first point of contact during interactions between various people. Injuries to the maxillofacial complex have a significant impact by causing severe morbidity, loss of function, disability, and financial burden to the affected person.⁸ The goal of treatment of bone fractures is to restore the mechanical strength of the bone fracture site to its healthy state and to increase normal muscle function mastication.⁹ Maxillofacial fractures are complex fractures involving the facial bones, classified by Rene Le Fort, who stated the skulls of corpses with blunt force trauma. Classification during Le Fort 1 to 3 according to the location of the fracture line to the bone involved. Maxillofacial fractures are characterized by facial swelling, asymmetrical face, subconjunctival ecchymosis, to periorbital bleeding (raccoon eye) with a flat face and an elongated appearance in the middle. Maxillary mobility is evaluated by stabilizing the patient's head by applying pressure to the forehead with one hand. The thumb and forefinger of the other hand grip the anterior maxillary rim, and pressure is then used to mobilize it. Patients often complain of an inability to find dental occlusion and maxillary mobility. Bilateral infraorbital nerve paresthesia may also occur. In this case, facial elongation, raccoon eyes, maxillary bone mobility, and non-intact occlusion were obtained, indicating that there was maxillofacial trauma, as mentioned by Anthony Lynhan in a journal entitled Maxillofacial Trauma, about clinical signs of maxillofacial fractures.^{9,11}

All cases of suspected midfacial fracture require a comprehensive CT scan, especially those with orbital bone

involvement. If a head injury is suspected or signs of a neurological deficit are found, the CT scan should include soft tissue and the brain. Plain radiographs such as Panoramic and Schedel can be useful where a CT scan is not accessible. The results of a CT scan can show facial fracture lines so that a diagnosis can be determined. In this case, the patient found fracture lines on the facial bones: bilateral frontonasal and fronto-zygoma; bilateral orbital rime medial and inferior aspects; left zygoma; nasal, maxilla, and mandibular symphysis. The patient's clinical and supporting examinations indicated a mild head injury from type 1 and Le Fort 3 naso-orbital-ethmoid fractures, type 2 palate, and mandibular symphysis. Le Fort III fractures involve the nasal bones, medial, inferior, and lateral orbital walls, pterygoid process, and zygomatic arch, completely separating the midface from the skull. This fracture affects the medial, lateral, transverse upper maxillary, and posterior maxillary buttresses. Similar to the Le Fort II fracture, which can be associated with orbital complications and CSF rhinorrhea. In this case, the patient was diagnosed with Le Fort III, but no rhinorrhea was found.^{6,7,11}

Multiple fractures of the facial bones can be a challenge to diagnose and treat. Even experienced surgeons find restoration of facial architecture difficult due to the severity of the fragmentation and the loss of reference segments that can guide facial reconstruction. Surgeons usually perform sequential reductions of facial bone fractures to restore facial contours. This sequential technique can be handled sequentially, namely the bottom-up and outside-in sequences, which are reported to be the most widely used in

Emergency Management of Multiple Maxillofacial Trauma Patients with Head Injury: A Case Report

recent publications. In this case, multiple facial fractures were found, and definitive treatment was carried out using a sequential system from bottom to top.^{9,12}

The initial management of patients with head injuries aims to monitor them as early as possible, prevent secondary head injuries, and improve their general conditions as optimally as possible.¹³ Emergency management of oromaxillofacial trauma patients must include immediate attention to the respiratory tract, adequate ventilation, control of bleeding (internal and external), and observation of cerebrospinal fluid leaks. Initial assessment (primary survey) in trauma patient cases is based on Advance Trauma Life Support (ATLS) from the American College of Surgeons (ACS). The primary survey is in the form of assessing airway clearance with C-spine control, breathing, ventilation, oxygenation, circulation, disability-neurologic status, exposure-environment, and body temperature (ABCDE).^{1,2,3}

ABCDE assessment is an examination priority based on the type of wound, vital signs, and mechanism of injury so that life-threatening conditions are quickly recognized, and immediate resuscitation is initiated. Examination of the airway in this patient found a clear airway with C-Spine control, intra-oral bleeding that did not interfere with the airway, and no obstruction. Efforts to free the airway are carried out by protecting the airway from intra-oral bleeding by suctioning and protecting the cervical vertebrae and installing a definitive airway if needed. There was no disturbance of the cervical spine through plain cervical X-rays, and no neurological deficits were found. In this case, the patient underwent emergency fluid resuscitation and blood transfusion due to a decreased hemoglobin value, which was based on multiple fractures accompanied by fractures of the long bones of the femur. The orthopedic department performed skin traction in the emergency room and waited for the general condition to be good enough to continue definitive action in the operating room. The first emergency oral surgery procedure to be performed is washing the wound, suturing it, reducing temporary fracture fragments, and immobilizing it using interdental and intermolar wiring.^{12,13}

Complications from trauma to the face, if not treated adequately, can lead to disfigurement and even minor changes in the face that are quite visible and noticeable. Therefore, complete fracture reduction is essential in cases of facial bone fractures. Facial nerve injuries can also be a complication, usually caused by blunt or penetrating trauma to the petrous portion of the temporal bone. Injury to the peripheral branches of the trigeminal nerve can arise from various procedures or injuries to the mouth and maxillofacial area. This can be a direct consequence of maxillofacial trauma or secondary to surgical intervention to repair facial trauma. Soft tissue complications may occur, including facial atrophy, nerve damage, shortening of the length of the upper lip, and widening of the alar bases. Infection is the most common complication, so using sterile tools and antibiotics must be considered.^{8,9}

After the emergency, the oral surgeon should closely examine the occlusal relationships to evaluate for an anterior or posterior open bite, a dental examination, mental nerve paresthesia, and the presence of trismus. The basic principles of fracture management are reduction, fixation, immobilization, infection prevention, and rehabilitation. The main goal of fracture treatment is to restore form and function before the injury with a minor disability, the least risk, and the shortest recovery period. The simplest method should be chosen if it is as effective as the more invasive methods. Treatment options may vary by country or region. Most patients underwent closed reduction treatment with arch bar fixation, and some needed further treatment with internal reduction open fixation mini plate installation. Miniplates have been reported as standard fixation devices for maxillofacial fractures. Conservative treatment was reserved for cases without occlusal changes or other functional problems. In cases of immobility, observation and elastic traction may be helpful. Open reduction allows anatomic repositioning and stable fixation of the fracture segment in all planes. During an open reduction, re-establishment of the occlusion is essential. Even in edentulous patients, establishing a maxillary-mandibular relationship is vital in treating Le Fort fractures.^{4,7}

Indications for surgery in maxillofacial fractures include disturbances in the orbit, aesthetic defects, and disturbances in the occlusion. This patient had occlusion disorders even though conservative therapy had been used using interdental and intermolar wiring. Aesthetic disturbances were also found in the presence of an asymmetrical face, so open reduction Internal fixation was performed following a closed reduction. Currently, ORIF has become the standard for fracture management because it provides stable three-dimensional reconstruction, improves bone healing, and shortens treatment time. Proper administration of antibiotics before surgery is recommended to prevent postoperative complications or infections. In this patient, definitive ORIF was performed under general anesthesia. After treatment, we obtained an excellent postoperative condition for the patient. The results related to facial contours, good maxillary and mandibular relations, and symmetrical facial features are satisfactory for patients, which indicates the importance of multidisciplinary treatment for the correction of maxillofacial fractures.^{3,4,6,7}

CONCLUSION

Physical trauma causes that result in multiple fractures of the maxillofacial bones are life-threatening and demand prompt and suitable specific treatment. Maintaining the airway and limiting bleeding are fundamental concepts in the emergency department's management of maxillofacial trauma. Once the patient is stable, emergency procedures for maxillofacial trauma may be carried out, such as wound debridement, wound closure, temporary repair of a fracture fragment, and immobilization to stop further bleeding and block the airway.

Emergency Management of Multiple Maxillofacial Trauma Patients with Head Injury: A Case Report

Once the patient's overall state is stable, definitive ORIF treatment currently the standard objective of excellent trauma management is started immediately to promote rapid recovery.

REFERENCES

- I. Patel BC, Wright T, Waseem M. Le Fort Fractures. [Updated 2022 Sep 12]. In: StatPearls [Internet]. Treasure Island (FL): StatPearls Publishing; 2022 Jan-. Available from: <https://www.ncbi.nlm.nih.gov/books/NBK526060/>
- II. Pswarayi, C. Burns, Le Fort III fractures: An approach to resuscitation and management, *Annals of Medicine and Surgery*, Volume 81,2022, 104513, ISSN 2049-0801, <https://doi.org/10.1016/j.amsu.2022.104513>.
- III. Daishi Arai, Akihiro Yasue, Shinya Horiuchi, Eiji Tanaka, "A Multidisciplinary Approach to Malocclusion Caused by Facial Multiple Fracture", *Case Reports in Dentistry*, vol. 2022, Article ID 5209667, 8 pages, 2022. <https://doi.org/10.1155/2022/5209667>
- IV. Fauzan Akmal, S. Adiantoro, AT. Yuza, A. Hardianto. Management of bilateral mandibular angle fracture: case report. *International Journal of Medical Reviews and Case Reports* (2022) 6(11):26-3
- V. Jose A, Nagori SA, Agarwal B, Bhutia O, Roychoudhury A. Management of maxillofacial trauma in emergency: An update of challenges and controversies. *J Emerg Trauma Shock*. 2016 Apr-Jun;9(2):73-80. doi: 10.4103/0974-2700.179456. PMID: 27162439; PMCID: PMC4843570.
- VI. Phillips BJ, Turco LM. Le Fort Fractures: A Collective Review. *Bull Emerg Trauma*. 2017 Oct;5(4):221-230. doi:10.18869/acadpub.beat.5.4.499..PMID: 29177168; PMCID: PMC5694594.
- VII. Oliveira-Campos GH, Lauriti L, Yamamoto MK, Júnior RC, Luz JG. Trends in Le Fort Fractures at a South American Trauma Care Center: Characteristics and Management. *J Maxillofac Oral Surg*. 2016 Mar;15(1):32-7. doi: 10.1007/s12663-015-0808-z. Epub 2015 May 26. PMID: 26929550; PMCID: PMC4759026.
- VIII. Wadde, K., Chowdhar, A., Ghodake, M., & Rathod, S. (2022). Evaluation of postoperative complications following management of mandibular fractures with open reduction & internal fixation under regional anaesthesia: A retrospective study. *International Journal of Health Sciences*, 6(S1), 22582267. <https://doi.org/10.53730/ijhs.v6nS1.5163>
- IX. Dergin, G. , Emes, Y. , Aybar, B. . Evaluation and Management of Mandibular Fracture. In: Gözler, S. editor. *Trauma in Dentistry* [Internet]. London: IntechOpen; 2019 [cited 2022 Oct 24]. Available from: <https://www.intechopen.com/chapters/65088> doi: 10.5772/intechopen.83024
- X. Rattan V, Rai S, Yadav S. Complications and Pitfalls in Maxillofacial Trauma. *J Postgrad Med Edu Res* 2014 ;48(2):91-97.
- XI. Lynham A, Tuckett J, Warnke P. Maxillofacial trauma. *Aust Fam Physician*. 2012 Apr;41(4):172-80. PMID: 22472677.
- XII. Kim J, Choi JH, Chung YK, Kim SW. Panfacial Bone Fracture and Medial to Lateral Approach. *Arch Craniofac Surg*. 2016 Dec;17(4):181-185. doi: 10.7181/acfs.2016.17.4.181. Epub 2016 Dec 23. PMID: 28913280; PMCID: PMC5556833.
- XIII. Rattan, Vidya, Sachin Rai, Shikha Yadav and Dhillon. "Complications and Pitfalls in Maxillofacial Trauma." *Journal of Postgraduate Medicine, Education and Research* 48 (2014): 91-97.