

## Congenital Left Paraduodenal Hernia: Report of a Case

Unzueta Jocelyn<sup>1</sup>, Amezcua Miguel<sup>2</sup>

<sup>1</sup>Hospital General de Zona #33 Monterrey, Nuevo León.

<sup>2</sup>IMSS Hospital General Regional 270 Reynosa, Tamaulipas.

### ABSTRACT

**Introduction.** Internal hernias represent the protrusion of intestinal loops through congenital or acquired openings into the mesentery or peritoneum. One such hernia is the paraduodenal hernia, which is the most common type of internal hernia (53%). Due to the variable and non-specific clinical presentation, the preoperative diagnosis of these hernias is difficult. Despite the available studies, they generally present with intestinal occlusion, making their diagnosis during laparoscopy or laparotomy. Preoperative abdominal computed tomography facilitates diagnosis and timely surgical intervention [3].

**Case presentation.** This paper presents the case of a 19-year-old male patient with left paraduodenal hernia. He came to the emergency room with severe abdominal pain. Diagnosis was established by computed tomography and a converted surgical procedure was successfully performed.

**Discussion:** Acute intestinal obstruction caused by a left paraduodenal hernia is a rare cause of intestinal obstruction.

**Conclusion.** The patient underwent an exploratory laparotomy and it was found that the herniated intestine was viable, for which it was decided to reduce it and close the defect, obtaining good clinical results in the patient.

**KEYWORDS:** paraduodenal hernia; internal hernias; Landzert's pit; Treitz; jejunum.

### ARTICLE DETAILS

**Published On:**  
**03 July 2023**

**Available on:**  
<https://ijmscr.org/>

### INTRODUCTION

An internal hernia can be defined as the protrusion of parts of internal organs (most commonly the small intestine) through normal (Winslow's foramen), paranormal (ileocecal, supramesocolic, paraduodenal) or abnormal (transmesocolic) mesenteric or peritoneal defects. These defects can be acquired (caused by abdominal surgery, trauma, peritoneal infection or ischemic processes, increased intra-abdominal pressure and consequent dilation of Winslow's orifice, omental atrophy) mainly the result of surgical operations, which are frequently observed after a few bariatric operations, especially the Roux-en-Y gastric bypass. Or congenital (they are more common in a virgin abdomen, and include paraduodenal (53%), paracecal (13%), Winslow's foramen (8%), transmesocolic (8%).

Internal hernias are rare and represent a major diagnostic and therapeutic challenge. Paraduodenal hernia, also known as Treitz hernias, is the most common form of internal hernia and occurs with an incidence of 30-53% of all internal hernias [5], causing 0.2 to 0.9% of intestinal obstructions [6]. Regarding gender, internal hernias occur 3 times more in men than in women.

Efficient diagnosis of a paraduodenal hernia is important to avoid complications such as intestinal ischemia, which is associated with high mortality.

In this article we describe the case of a left paraduodenal hernia in a 19-year-old man who presented to hospital with acute abdominal pain, diagnosed by abdominal CT and successfully treated by open surgery.

### CASE REPORT

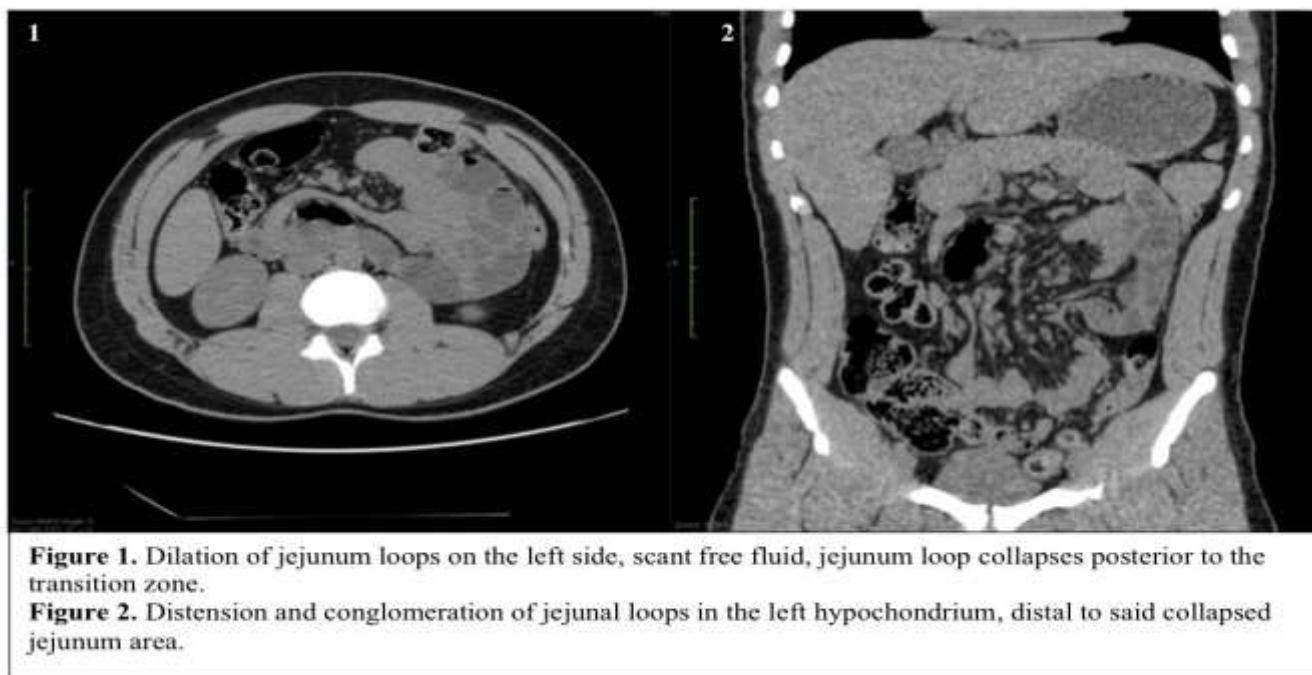
This is a 19-year-old male patient with a denied medical history. Admission to the emergency department with a clinical picture of 24 hours of evolution characterized by generalized intermittent intense abdominal pain, accompanied by abdominal distension, nausea and vomiting, without fever, with present evacuations, channeling gases. As an antecedent of importance, 5 years of evolution with occasional abdominal pain secondary to food intake.

On physical examination, the abdomen was soft, without distension, generalized pain on palpation, positive rebound, decreased peristalsis.

## Congenital Left Paraduodenal Hernia: Report of a Case

Laboratories: Hemoglobin 14.5, hematocrit 43.7, platelets 272, leukocytes 7.9, neutrophils 72, glucose 95, creatinine 0.5, BUN 9, urea 19.3, total cholesterol 108, BT 1.1, BD 0.3, total protein: 7.6, albumin 4.6, sodium 132, K 5, Chlorine 97

CT: distended small bowel loops in the left hypochondrium, with a transition zone, distal to this loops of jejunum collapsed, little free fluid. (Figure 1 and 2)



She was admitted for medical management, analgesia, and hydroelectrolytic management, without presenting improvement in a period of 8 hours, evolving with intolerance to the oral route and persistent abdominal pain.

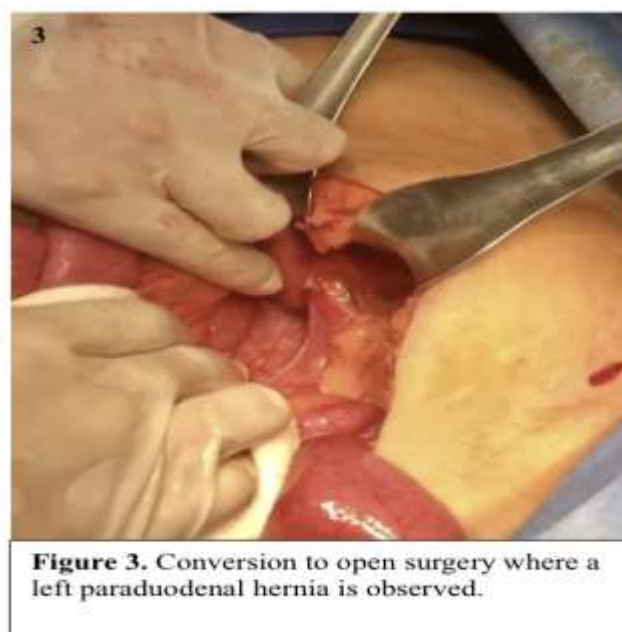Diagnostic laparoscopy was scheduled where an incarcerated paraduodenal hernia of approximately 50 cm of jejunum was evidenced, conversion to open surgery was decided, a midline incision was made and when exploring the cavity a left paraduodenal hernia was detected containing 50 cm of jejunum loops. the hernial content was reduced, finding viability in the affected segment, it was decided to close the hernia site with 2-0 prolene. (Figure 3)

Currently, after one year of postoperative follow-up, he remains asymptomatic, tolerating the oral route, with no evidence of intestinal occlusion.

### DISCUSSION

There are two types of paraduodenal hernias: left-sided (75%) and right-sided (25%). [4]. The clinical presentation of the paraduodenal hernia varies from asymptomatic, through non-specific symptoms, such as digestive disorders and chronic abdominal pain, to symptoms of intestinal obstruction. Diagnosis is made based on the clinical history, clinical examination of the patient, and preoperative computed tomography. Despite the diagnostic possibilities indicated, the final diagnosis is made during surgery in most cases.

Treatment consists of surgery, either in the form of open surgery or laparoscopy. Laparoscopic surgery is preferred by



experienced surgeons in high volume centers. Recovery after the laparoscopic procedure is faster, but the long-term results are similar for both methods.

There are numerous classifications of internal hernias, and one of the most acceptable is the one suggested by Welch, who divides internal hernias into 8 types: 1a: left paraduodenal hernia, 1b: right paraduodenal hernia, 2: Winslow foramen hernia, 3: pericecal hernia. hernia; 4: hernia related to the sigmoid mesocolon; 5: transmesenteric hernia;

## Congenital Left Paraduodenal Hernia: Report of a Case

6: transomental hernia; 7: supravescical and pelvic hernia. Classify internal hernias into 3 main groups according to the type of hernia opening (normal opening, recess in retroperitoneum or unusual peritoneal fossa, and abnormal opening in mesentery or peritoneal ligament) [3].

Left paraduodenal hernias (LPDHs) occur when the proximal jejunum or parts of the duodenum prolapse through the paraduodenal fossa or Landzert's fossa. This is an opening at the duodenojejunal junction (the junction of the transverse mesocolon, descending mesocolon, and small bowel mesentery), behind the descending mesocolon and to the left of the fourth segment of the duodenum. Pathologically, in LPDH, the small bowel loops enter posteroinferiorly through the mesocolic defect and become trapped in Landzert's fossa, extending further into the descending mesocolon and the left half of the transverse mesocolon [3].

The cause of this opening is an embryonic disorder in terms of the lack of connection of both peritoneal folds from the sixth to the eleventh week of gestation. The mean age of onset of paraduodenal hernia is 44 years [3].

The clinical presentation of the paraduodenal hernia varies from asymptomatic to symptoms such as: abdominal pain (as the most common symptom), vomiting, nausea and symptoms of intestinal obstruction. Among the rarer symptoms that can be mentioned are secondary pancreatitis, biliary colic, and palpable swelling in the upper left part of the abdomen. The symptoms in most cases are non-specific and last for years. The greatest difficulty in the management of paraduodenal hernias lies in their diagnosis, especially in the case of asymptomatic patients or with non-specific symptoms of a chronic nature. The definitive diagnosis is made during surgery or autopsy [3].

Definitive treatment of LPDH involves surgery, which can be performed laparoscopically or openly. The procedure involves freeing the intestinal loops from the hernia sac and repairing the defect by widely closing or opening the hernia orifice, whereby the hernia sac becomes part of the peritoneal cavity [3].

Left HDPs are often associated with a smaller sac, allowing for easier reduction of the small intestine, followed by closure of the hernial defect. However, in cases where the small intestine cannot be smoothly reduced, enlargement of the hernia defect can be performed, but requires close attention, to avoid iatrogenic injury to the IMV, which is an integral component of the sac. hernial. In the worst case of an IMV injury, this vessel can be ligated, as described in other reports [6].

Treatment methods include exploratory laparotomy as well as laparoscopic hernia repair. Minimally invasive hernia repair is a relatively new technique and the first laparoscopic repair of this type of hernia was reported in 1998 [6].

Laparoscopy has advantages in reducing postoperative pain and the patient's hospital stay. It is recommended for uncomplicated cases, where there is no suspicion of

strangulation or perforation. However, the long-term results are similar in terms of the open and laparoscopic techniques. If the patient presents with an acute complication, an open approach is recommended; however, if the symptoms disappear, then the minimally invasive approach is preferred [2].

## CONCLUSION

This paper presents the case of a 19-year-old male patient with LPDH with non-specific symptoms. Due to the persistence of abdominal pain, nausea and vomiting after meals as a consequence of the intestinal obstruction, a surgical schedule was decided. It was approached laparoscopically and in view of the findings it was decided to convert to exploratory laparotomy, which confirmed the formation of LPDH, and was resolved in the usual way, releasing the trapped loops of the small intestine and closing the hernia orifice with sutures. Unrecognized LPDH leads to delayed surgery, which can cause intestinal perforation, peritonitis, and even death.

## REFERENCES

- I. Kadhem S, Ali MH, Al-Dera FH, Alzayer NA, Alyagoub HM. Left paraduodenal hernia: case report of rare cause of recurrent abdominal pain. *Cureus*. 2020; 12:e7156.
- II. Kabbani D, Salem A, Holloway DK. Paraduodenal herniation: an internal herniation in a virgin abdomen. *Int J Surg Case Rep*. 2014; 5:1148-1150.
- III. Manojlović D, Nenad C, Palinka M. Left paraduodenal hernia – A diagnostic challenge: Case report; 2021. <https://doi.org/10.1016/j.ijscr.2021.106138>.
- IV. Wakabayashi M, Kono S, Takahashi T. Laparoscopic repair of acute small bowel obstruction due to left paraduodenal hernia: A case report. *Int J Surg Case Rep*. 2018; 51: 194-199.
- V. RA Brigham, WF Fallon, JR Saunders, et al., Paraduodenal hernia: diagnosis and surgical management, *Surgery* 96 (1984) 498–502 .
- VI. Schizas D, Apostolou K, Krivan S, Kanavidis P, Katsaros I, Vailas M, Koutelidakis I, Chatzimavroudis G, Pikoulis E. Paraduodenal hernias: a systematic review of the literature. *Hernia*. 2019 Dec;23(6):1187-1197. doi: 10.1007/s10029-019-01947-3. Epub 2019 Apr 20. PMID: 31006063.