

Complication in Neglected Non-Venomous Snake Bite in Rural Area; What We Need to Anticipate

Almira Talitha Ulima¹, Ahmad Fawzy²

¹Rantau Suli Public Health Center, East Jangkat, Jambi, Indonesia

²Department of Surgery, Universitas Jendral Soedirman, Indonesia

ABSTRACT

Snake bite is common condition that lead to great consequence in the rural area of tropical country. Although snakebite is treatable, WHO listed snakebite as Neglected Tropical Disease. Epidemiology data of snakebite not known exactly, the real data may be higher than data inscribed. Both venomous and non-venomous snake are can lead to fatal condition and make the victim consequences morbidity and mortality. Non-venomous snakebite also have potential risk of infection, coagulopathy, and traumatic feelings. Prognosis affected by many factors from snake venom, the victim, and environment that led to delayed medical treatment. Here, we report a case of neglected non-venomous snakebite wound that lead to severe infection of the limb.

KEYWORDS: snake bite, non-venomous snake, infection, neglected tropical disease

ARTICLE DETAILS

Published On:
08 October 2022

Available on:
<https://ijmscr.org/>

BACKGROUND

Snake bite is common condition that lead to great consequence in the rural area of tropical country, it cause death and many more patient permanently disabled, although snake bite is treatable, World Health Organization listed this problem as Neglected Tropical Disease.^{1,2} The incidence of snake bite worldwide is estimated about 4.5–5.4 million people, 1.8–2.7 million people with envenomation and causes 81000 - 138000 death. Most snake bites occur in rural tropical regions of sub-Saharan Africa, Asia, and South America, where snake are numerous and many inhabit are agrarian, with India alone contributed 50% annual death case.^{3,4} In this world, more than 3000 species of snakes with 660 kinds are venomous snakes and about 60%-80% are non-venomous bites, but only 250 are medically important venomous snake.^{5,6} Both venomous and non venomous snake-bite are dangerous and can be fatal⁷⁻¹⁰ South-East Asia has the highest number case snake bite, with three families of venomous snakes which often causes envenomation that is Elapidae, Viperidae and Colubridae.^{11,12} Accurate worldwide statistics about snake bite management in both developing and developed country are lacking due to not well established surveillance system and difficulties to count about the actual numbers involved because of many factors and reasons.^{1,13-15} Number of snake bite in developed country is less, linked to their modern life and easy access to the professional treatment

center, the incidence may increase as people doing outdoor activities and adventure increases.^{15,16} Meanwhile, in developing country, the tardiness factors of management and access to antivenom affected by scarcity of antivenom issue, lack of protocol on snake bite envenoming management as many health workers not trained well on snakebite management, far and deplorable roads that linked to poor hospital access, financial issues for whole treatment and long travel distance to reach hospital, and tradition with strong belief of the victim who seeking help to traditional health practitioner or the quack first before reach primary health care.^{1,17, 13-14,18-20}

These condition make snake bite as Neglected Tropical Disease as WHO listed.² Neglected Tropical Disease is a group of disease that attack more than billion inhabitants in tropical and subtropical countries caused by a variety of pathogens such as viruses, bacteria, protozoa and helminths which underestimated as important diseases, this may lead to increased social burden, decresed economy and productivity and stigmatization due to long life's deformities and handicaps, decrease productivity and economic status as well as many social burden and stigmatization.²¹⁻²³ Complication following snake bite caused by venom composition which are composed from several dangerous enzyme, necrotoxins, neurotoxins, cardiovascular toxins, pain-producing toxins,

Complication in Neglected Non-Venomous Snake Bite in Rural Area; What We Need to Anticipate.

biogenic amines.⁷ Even the victims of snake bite are still survived, they may experience several complications include short term and long term complications that lead to chronic disability or death.^{7, 17, 24, 25} Here we present about a case of neglected non-venomous snake bite in rural area that leads to cellulitis of the limb.

CASE PRESENTATION

A 39-year-old female farmer came to local primary health care in rural area in East Jangkat, Indonesia. Patient complained swelling in her left foot and ankle after an exposure to a snake bite. Patient felt her left foot worsening since 2 days before she went to primary health care. Patient said that she was bitten in the left foot by a green-coloured snake 24 days ago when she worked in her groves. Patient does not use appropriate personal protective equipment. Appearance and features of the snake were not identified because patient only saw the snake at a glance. Patient admitted that the snake bite wound was like scratch-like shaped, not two fang shaped wound. Her bitten foot became painful and her left foot movement limited resulting patient must lift her left foot when walking. From snake bite event until she went to primary health care, history of fever, dyspnoea, loss of consciousness, cyanosis, abnormal hemorrhage from nose or mouth is denied by patient. There is no disorder of vision or neurologic deficit. History of diabetes mellitus, hypertension, abnormal bleeding, allergic toward food and drug was denied by patient. Patient never received anti-venom or history bitten by venomous animal. Family history of abnormal bleeding was denied. When patient bitten by snake, patient tied her foot on the left ankle and went to local midwife in her village immediately. She

got paracetamol from local healthcare worker and referred to emergency department in local primary health facility. Patient went to emergency department 8 hours after she was bitten. She got medication from doctor that were mefenamic acid 3 x 500 mg PO, dexamethasone 3 x 0,5 mg PO, amoxicillin 3 x 500 mg PO. Patient was educated and motivated by doctor to go to the hospital, but patient preferred to return to her home in the village because of financial issues and she can't afford whole treatment including travel fare to the hospital located 6 hours away from the village. Patient neglected this wound 24 days until she came again to local primary health care to seek professional medical help. History of seeking treatment to quack or traditional healers was not clear.

On physical examination, the patient was fully conscious and calm. Blood pressure measured 120/70, pulse rate 72x/m regular, equal, full, respiration 18x/m. Weight and height are unknown, but patient seems to be overweight. General status is within normal limits. On local examination found swelling and erythema in cruris sinistra and pedis sinistra with oedema and numbness in dorsum pedis sinistra area, limited range of motion of the left ankle. Dorsalis pedis artery pulsation cannot be detected. Fang marks shape of snake bite have not been seen, just seems pus oozing out from small draining port with 0,3 cm diameter. When pus has been removed, seems a yellow-coloured-dense tissue in draining port. Laboratory examination cannot be performed because of limited equipment and facilities. From anamnesis and physical examination revealed diagnosis cellulitis post-snakebite.

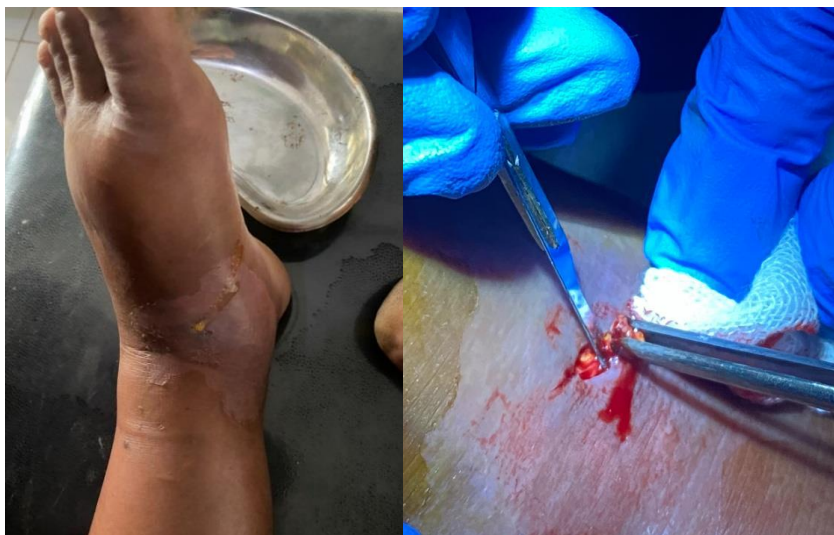

Figure 1. (a) Pus oozing out from small draining port with 0,3 cm diameter in the bitten limb. (b) Fibrinopurulent pus with yellow-coloured-cheese like appearance,

In patient performed incision and drainage to remove the congealed pus, 2 cm incision has been made and revealed the fibrinopurulent pus with yellow-coloured-cheese like appearance. Blunt dissection performed around incision to explore the fibrinopurulent pus. The reachable part of

fibrinopurulent pus removed, but not fully removed because the infected area was so extensive and the area cannot be incised widely with limited conditions and facilities. Finally, patient was educated and referred to the hospital for further treatment. The patient is given temporary medication while waiting to

Complication in Neglected Non-Venomous Snake Bite in Rural Area; What We Need to Anticipate.

be referred, that are Mefenamic Acid 3 x 500 mg and Cefadroxil 2 x 500 mg. The last time patient came to the primary health care to evaluate the wound but now she not present yet according to geographic obstacle.

DISCUSSION

In this case report, patient was bitten by unknown snake species and information of the snake was limited because patient only saw the snake at a glance. Bite marks has disappear, but from patient information, no fang shaped in bite marks. We presume that the patient was bitten by non-venomous snake. It is important to distinguish whether the snake is venomous or non-venomous to avoid the mosspotential of diagnosis, this can be recognized from superficial appearance of the snake and envenomation symptoms, but its better if the snake brought to healthcare facility for further identification.^{7,8} Few characteristics of snake can help us to identify whether its venomous or non-venomous snake. Venomous snake have more triangular-shaped head (except elapids group) with pointed snout, broad neck with constriction in the neck, elliptical shaped cat like pupil, triangle shaped head with or without small depression

termed facial pit between the eyes and nostrils (for heat regulation and detection of warm-blooded prey and predators even in the dark)¹¹, grooved or hollowed fangs, relatively thick body, rough scales, all have single row of anal scale (the very tip of the tail may possess two scale rows), with rattle in rattlesnake, colorful and repeated pattern on dorsal, have hood (cobra), Red/pink markings on throat (spitting cobra). Non-venomous snake known with round shaped jaw, round snout, round pupil in the centre of eye, no sensory pits, no fangs just multiple teeth on the upper jaw and in the lower jaw, relatively thin body, two rows of scales from the vent to the end of tail, uniformly coloured or lack of repeated dorsal pattern, no hood. Characteristic also can be identified by observing the behavior of the snake. Venomous snake are more aggressive, emitting a warning sound (rattling), head and body are seen during swimming time, bitten wound shaped two fang marks while non-venomous snake shaped a ragged bite mark. There are some exception round-shaped head in coral snake, colorful snakes that are non-venomous that is scarlet snake, king snake, milk snake, snake with round pupil which are venomous as found in black mamba, coral snake, cobra.^{7,8,11-12,17,26-28}

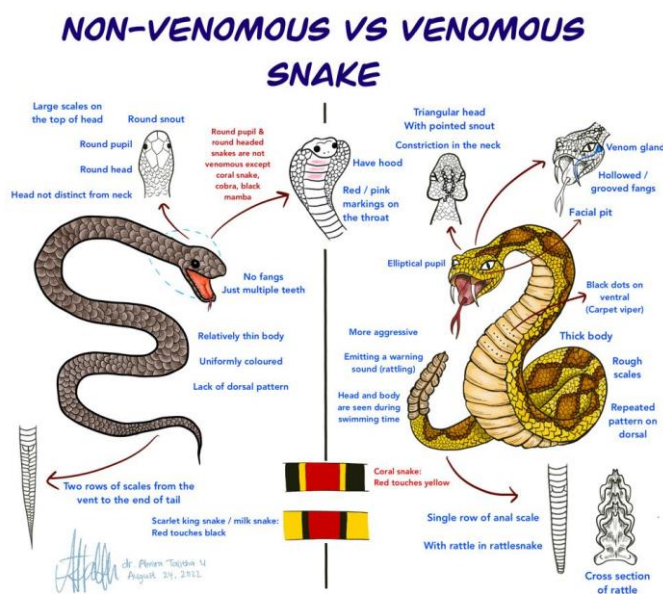


Figure 2. Difference between venomous and non-venomous snake

From data extraction in this case, local examination in this patient revealed swelling and erythema in cruris sinistra and pedis sinistra with oedema and numbness in dorsum pedis sinistra area, limited range of motion of the left ankle and pos oozing out from draining port. Both venomous and non-venomous snake can lead to tissue infection.⁷ Even if the snake are identified as non-venomous, although complication is rare, it may bring morbidity because of many factors. Non-venomous snake also have potential risk of infection due to contaminated saliva of the snake when bite the victim, it could be flora from snake's oral cavity, skin bacteria of victim skin, environmental contamination of bite or inappropriate management.²⁹ Bacterial type of snake oral cavity are reflection of their prey or what they ingested and variated of aerobic and anaerobic microorganism.^{30,31} Severe wound

infections following snakebites such as cellulitis and necrotizing fasciitis are not common, only 30.8% reported.³² The average time from snakebite to infection was 6 days.³³ Gram-positive bacteria are frequent than gram-negative bacteria. The most common gram-positive bacteria in snakebite is Staphylococcus aureus and the most common gram-negative bacteria is Escherichia coli Although bacteria are common cause of wound infection, the use of prophylactic antibiotic is still controversial.³¹ Beside of wound infection, snake bite also causes understandable fear of the bite that leads to pins-and-needles sensation in the extremities, dizziness vasovagal shock, extreme agitation^{6,11,12,34} In long-term impact, the victim may experience of chronic or recurrent symptoms in the bitten site, traumatic feelings because unforgettable and dramatic event

Complication in Neglected Non-Venomous Snake Bite in Rural Area; What We Need to Anticipate.

when bitten.⁷ The bite of non-venomous snake are not always harmless, from the case red-neck keelback (*Rhabdopsis subminiatis*) as a pet striking their owner, the victim run into coagulopathy with bleeding diathesis, although it is self limiting.³⁵ Depending on size, a bite of a non-venomous snake can be significant if the tooth is big as in the phyton snake, or coincidence the tooth can be detached during a bite and leave foreign body embedded in bite site.³⁶ Meanwhile, infection in venomous snakebite resulted from Local envenomation causes by proteolytic enzymes (endopeptidases) which increase vascular permeability leading to swelling, bruising, blistering, tissue necrosis, severe local pain in coral snake envenoming. Beside of enzymes, tissue necrosis/gangrene caused by myotoxins, cytotoxins, metalloproteinases, or secondary ischaemia because use of tourniquet, compartement syndrome leads to peripheral nerve lesion. Skin and muscle damage caused by snakebite envenoming are constitute infection bed and favorable for bacterial colonization.³³ Chronic ulcers, pyogenic arthritis, osteomyelitis, Marjolin's ulcer (malignant transformation) can happen in chronic complication. Cellulitis and necrotizing fasciitis after venomous snakebite are not common, but require aggressive treatment such as fasciotomy if it happens.³⁷ Cellulitis can lead to joint dislocation if no early treatment taken.³⁸ Therapy with antivenom can reduce effect in systemic, but cannot help the effect of local tissue destruction and it will be constantly lead to necrosis.³²

In addition, the patient in this case seems overweight and it is also risk factor that increase soft tissue swelling and infection and delayed wound healing. Overweight patient are expected to suffer hyperglycemia, skin and soft tissue infections correlated with prolonged hospitalization due to delayed wound healing.³⁹

The patient neglected her wound 24 days until seeking help again to medical professional because financial issues and she cannot afford whole treatment include travel fare to go to hospital located 6 hours away from the village. When she came, it is too late, the pus has change to fibrinopurulent tissue and spread widely under the skin. She had cellulitis post-snakebite and must be referred to hospital.

Several factors that delay treatment are far distance, poor infrastructure and lack of transport to reach hospital. Socioeconomic problem and poverty is significant deterrent in rural community, the victim cannot afford cost of the whole adequate treatment including transport fee, pricey snake-antivenom, and long-term hospitalization caused by snake bite.⁴⁰⁻⁴¹ In addition, there is lack of knowledge about snakebite in rural community, patients prefer seek help to traditional health practitioner or quack before seeking care to medical professional, they have cultural belief to more trust the quack because they believe snake as manifestation from their ancestor and snake are used in witchcraft practice, so they prefer seek help first to quack to gain supranatural help.^{18,42} Harmful treatment by quack also contribute in neglected snake bite.⁴¹ Abbas et al reported two case of snake-bite gangrene in children, these cases are example that people in rural area prefer to choose traditional healer initially, so their inappropriate traditional treatment delayed

medical treatment led the victims to major limb amputation and long-life handicap.⁴³ Unwitnessed snake bite also factors that delay treatment because the victim unrealized that they bitten by snake and come late to healthcare facility with toxic appearance from local or systemic envenoming.⁴⁰

In general, fatality of snake bite depends on many factors such as dose of venom injected by snake, composition and potency of venom, size, age and specific immunity to snakebite victim, timing to reach first aid and medical treatment, comorbid factor.¹⁰ We must wary of every snake bites, even the snake are non-venomous, it can be causes morbidity because of many factors such as potential risk of infection due to contaminated saliva of the snake when bite the victim, it could be flora from snake's oral cavity, skin bacteria of victim skin, environmental contamination of bite or inappropriate management.^{29,30} So, non-venomous snakebite must not underestimated and also get attention from society.

CONCLUSION

Snakebite is neglected disease that causes burden especially in rural society. Proper knowledge to identify and differ the characteristic of snake types and its bite will help us to decide appropriate management for patients. We must not underestimate every snakebite cases, even it is a non-venomous snake bite. With many factors, non-venomous snakebite can be lead to worsening condition as severe infection, increase morbidity, and consequences long-term handicap.

REFERENCES

- I. Chippaux JP. Snake-bites: appraisal of the global situation. Bull World Health Organ. 1998;76(5):515-24
- II. Sminkey L. World report on child injury prevention. Inj Prev. 2008;14(1):69.
- III. WHO. Snakebite. Accessed on July, 19th 2022. https://www.who.int/health-topics/snakebite#tab=tab_1
- IV. Mahmood et al. Inadequate knowledge about snakebite envenoming symptoms and application of harmful first aid methods in the community in high snakebite incidence areas of Myanmar. PLoS Negl Trop Dis. 2019;13(2): e0007171. DOI: <https://doi.org/10.1371/journal.pntd.0007171>
- V. Wang, Haiyan. Epidemiological characteristics and morbidity of Snake-bites in Zunyi city, China
- VI. Bawaskar et al. The global burden of snake bite envenoming. J R Coll Physicians Edinb. 2021; 51: 7–8. DOI: 10.4997/JRCPE.2021.102
- VII. Auerbach, Paul S. Auerbach's Wilderness Medicine 7th Ed. Philadelphia: Elsevier; 2016.
- VIII. Johnson, Chris. Oxford Handbook of Expedition and Wilderness Medicine 2nd Ed. United Kingdom: Oxford University Press; 2015

Complication in Neglected Non-Venomous Snake Bite in Rural Area; What We Need to Anticipate.

- IX. Kanaan NC, Ray J, Stewart M. Wilderness Medical Society Practice Guidelines for the Treatment of Pitviper Envenomation in the United States and Canada. *Wilderness Environ Med.* 2015; 26: 472-487.
- X. Huang, Li. Wound infections secondary to snakebite in central Taiwan. *J Venom Anim Toxins incl Trop Dis.* 2012; 18(3)
- XI. Alirol, et al. Snake Bite in South Asia: A Review. *PLoS Negl. Trop. Dis.* 2010, e603
- XII. WHO. Guidelines for the Management of snakebites 2nd Ed; 2016.
- XIII. Sachett et al. Bothrops atrox Snakebite: How a Bad Decision May Lead to a Chronic Disability: A Case Report. *Wilderness & Environmental Medicine* XXXX; XXX(XXX): 1-7
- XIV. Thapar R, Darshan BB, et al. Clinico-epidemiological profile of snakebite cases admitted in a tertiary care Centre in South India: A 5 years study. *Toxicol Int* 2015; 22:66-70.
- XV. Yasunaga H, et al. Short Report : Venomous Snake Bites in Japan. *Am. J. Trop. Med.Hyg.* 2011; 84(1): 135–136.
- XVI. Park et al. Effectiveness of repeated antivenom therapy for snakebite-related systemic complications. *Journal of International Medical Research.* 2019; 47(10): 4808-4814
- XVII. Kumar B. National Guidelines For Snakebite Management In Nepal. Kathmandu: Government of Nepal, Departement of Health and Services; 2019.
- XVIII. Sloan et al. Healthcare-seeking behaviour and use of traditional healers after snakebite in Hlabisa sub-district, KwaZulu Natal. *Tropical Medicine and International Health* 2007; 12(11): 1386-1390
- XIX. Patikorn C, et al. Situation of snakebite, antivenom market and access to antivenoms in ASEAN countries. *BMJ Global Health* 2022;7:e007639. DOI:10.1136/bmjgh-2021-007639
- XX. Eljaoudi R, Larréché S, Chakir S, Chafiq F, Hmyene A, et al. Snake bites in morocco: Progress and challenges. *Adv Toxicol Toxic Effects.* 2019; 3(1): 009-014. DOI:<https://dx.doi.org/10.17352/atte.000004>
- XXI. WHO. Neglected tropical diseases. Draft road map for neglected tropical diseases 2021–2030; 2020.
- XXII. Yuniasih D, et al. Snakebite as a Neglected Tropical Diseases in Indonesia: A Review. *International Journal of Scientific & Technology Research.* 2020; 9(3): 6180-185
- XXIII. Kindhauser, Mary Kay & World Health Organization. Communicable diseases 2002 : global defence against the infectious disease threat. 2003. Accessed on August, 2nd 2022 <https://apps.who.int/iris/handle/10665/42572>
- XXIV. Kang HY et al. Mallet finger deformity after snake bite. *J Wound Manag Res* 2019 September;15(2):117-120
- XXV. Gold, et al. Bites of venomous snakes. *N Engl J Med.* 2002; 347(5)
- XXVI. Kanaan N. Wilderness Medical Society Practice Guidelines for the Treatment of Pitviper Envenomations in the United States and Canada. *Wilderness & Environmental Medicine.* 2015; 26: 472–487
- XXVII. Vijayababu, et al. Credentials of poisonous and non-poisonous snake – A mini review. *Mol Biol.* 2021; 10(4)
- XXVIII. Briggler J. A Guide to Missouri’s Snakes. Missouri Departement of Conservation; 2017
- XXIX. Muhammad H, et al. Multidrug-resistant infection following snakebite envenoming: A case report. *Niger J Basic Clin Sci* 2018;15:161-3.
- XXX. Dehghani et al. A survey on Non-Venomous Snakes in Kashan (Central Iran). *J. Biol. Today's World.* 2016; 5 (4): 65-75. doi:10.15412/J.JBTW.01050402
- XXXI. Garg, A., Sujatha, S., Garg, J., Acharya, N.S. and Parija, S.C. Wound infections secondary to snakebite. *The Journal of Infection in Developing Countries.* 2009; 3(03):221-223.
- XXXII. Sadeghi et al. Massive cutaneous complications due to snakebite: A case report and literature review. *Clin Case Rep.* 2021. DOI: 10.1002/ccr3.4129
- XXXIII. Houcke, et al. Characteristics of Snakebite-Related Infection in French Guiana. *Toxins* 2022; 14, 89. <https://doi.org/10.3390/toxins14020089>
- XXXIV. Ahmed S, et al. Emergency treatment of a snake bite: Pearls from literature. *J Emerg Trauma Shock.* 2008; 1(2): 97-105
- XXXV. Seow et al. Morbidity After a Bite from a ‘Non-Venomous’ Pet Snake. *Singapore Med J.* 2000; 41 (1): 34
- XXXVI. Herman et al. Nonvenomous Snakebite. *Annals of Emergency Medicine.* 1998; 17(11)
- XXXVII. Ganeshbabu, et al. Newer Lights in Management of Snake Bite Cellulitis, Surgical Vs. Medical. 2016; 15(8): 34-40
- XXXVIII. Balaji, et al. Snake bite induced cellulitis leading to infected open dislocation of the first metacarpophalangeal joint – A rare complication. *Journal of clinical ortopaedics and trauma.* 2015; 6: 195 – 198
- XXXIX. Özbulat et al. Factors Affecting Prognosis in Patients with Snakebite. *Eurasian J Emerg Med.* 2021;20(1): 6-11
- XL. Lamb, Thomas. Challenges in diagnosis and management of snake bites in resource poor

Complication in Neglected Non-Venomous Snake Bite in Rural Area; What We Need to Anticipate.

- settings: A case report of suspected Russell's viper envenomation. *Indian J Case Reports*. 2016; 74(1)
- XLI. Pach S, et al. Paediatric snakebite envenoming: the world's most neglected 'Neglected Tropical Disease'?. *Arch Dis Child* 2020; 105: 1135–1139. doi:10.1136/archdischild-2020-319417
- XLII. Nann S. How beliefs in traditional healers impact on the use of allopathic medicine: In the case of indigenous snakebite in Eswatini. *PLoS Negl Trop Dis*. 2021; 15(9): e0009731. <https://doi.org/10.1371/journal.pntd.0009731>
- XLIII. Abbas et al. Snake-Bite Gangrene in Children: A Report of Two Cases. *Journal of Surgical Technique and Case Report*. 2009; Vol. 1 No. 1