

Asymptomatic Presentation of Large Stomach Gastrointestinal Stromal Tumour (GIST) in an Elderly Patient: A Case Report

Min Nay Zar Wyke¹, Min Htet San², Zaw Lin Maung³, Thant Lwyn San⁴, Khin Aung Htun⁵

^{1,2,3}Consultant Surgeon, No. (1) Military Hospital (700-Bedded), Pyin Oo Lwin, Myanmar

⁴Professor and Head of Department of Surgery, Defence Services Medical Academy, Yangon, Myanmar

⁵Rector and Senior Consultant Surgeon, Defence Services Medical Academy, Yangon, Myanmar

ABSTRACT

Gastrointestinal stromal tumors (GISTs) are the most common mesenchymal neoplasms of the gastrointestinal tract, accounting for approximately 1% of all gastrointestinal cancers. They primarily arise from the interstitial cells of Cajal in the gastrointestinal wall and can occur throughout the digestive tract, most frequently in the stomach. While symptomatic cases often present with gastrointestinal bleeding, obstruction, or abdominal pain, large tumors can remain asymptomatic for long periods, leading to incidental detection. This case report discusses an 80-year-old woman with a 20-year history of a painless upper abdominal mass, initially presenting without gastrointestinal symptoms, obstruction, or constitutional complaints. Imaging suggested a large GIST, and after surgical resection, histopathology confirmed an epithelioid GIST of the stomach. This case highlights the unusual asymptomatic course of a large gastric GIST and discusses the potential complications, such as rupture, obstruction, and pressure effects, that can arise from tumors of this size, underscoring the importance of early detection and management.

KEYWORDS: Gastrointestinal stromal tumor (GIST), asymptomatic, gastric mass, elderly patient, laparotomy, surgical resection, histopathology.

ARTICLE DETAILS

Published On:
10 October 2024

Available on:
<https://ijmscr.org/>

INTRODUCTION

Gastrointestinal stromal tumors (GISTs) are mesenchymal tumors of the gastrointestinal tract, accounting for less than 1% of all gastrointestinal malignancies. GISTs are believed to originate from the interstitial cells of Cajal, which serve as pacemaker cells regulating gastrointestinal motility. These tumors most commonly occur in the stomach (60-70%), followed by the small intestine (20-30%) (1).

GISTs typically present with non-specific symptoms such as abdominal pain, gastrointestinal bleeding, or signs of obstruction (1). However, a subset of GISTs, particularly those located in the stomach, can grow to significant sizes before becoming clinically evident. Asymptomatic cases, such as the one presented here, are often discovered incidentally during imaging for other conditions or through palpable masses upon physical examination (2).

In the case of large tumors, like the one in this report, there is a higher risk of serious complications, including rupture, bleeding, or pressure effects on adjacent organs (3). These

complications can lead to emergency situations requiring urgent intervention (4). Despite the large size of the tumor, the patient in this case remained asymptomatic, raising important considerations for the management of large, asymptomatic GISTs.

CASE PRESENTATION

An 80-year-old woman presented with a painless upper abdominal mass that she had first noticed 20 years earlier. The mass had been gradually increasing in size, but she denied any associated symptoms, such as abdominal pain, bloating, vomiting, dysphagia, or changes in bowel habits. There were no pressure-related symptoms, such as features of gastric outlet obstruction or intestinal obstruction, and the patient reported no constitutional symptoms like fever, weight loss, or fatigue. Her medical history included hypertension, for which she was on medication.

On physical examination, the patient was stable, with normal vital signs. Abdominal examination revealed a large, non-

Asymptomatic Presentation of Large Stomach Gastrointestinal Stromal Tumour (GIST) in an Elderly Patient: A Case Report

tender mass in the epigastric and paraumbilical regions. The mass was slightly mobile but not freely, and there was no evidence of peritonism. The rest of the abdominal examination was unremarkable, with no organomegaly or ascites.

Ultrasound (USG) of the abdomen revealed a heterogeneous mass measuring 14 x 11.3 x 16.8 cm, occupying the left side of the abdomen, likely originating from the stomach or transverse colon. Contrast-enhanced computed tomography (CECT) of the abdomen suggested a malignant GIST arising from the greater curvature of the body of the stomach, measuring approximately 20 x 18 cm (Figure 1). The tumor showed mucosal invasion into adjacent stomach tissue and displaced the transverse colonic loops. Hepatomegaly was noted, but there was no ascites or lymphadenopathy.

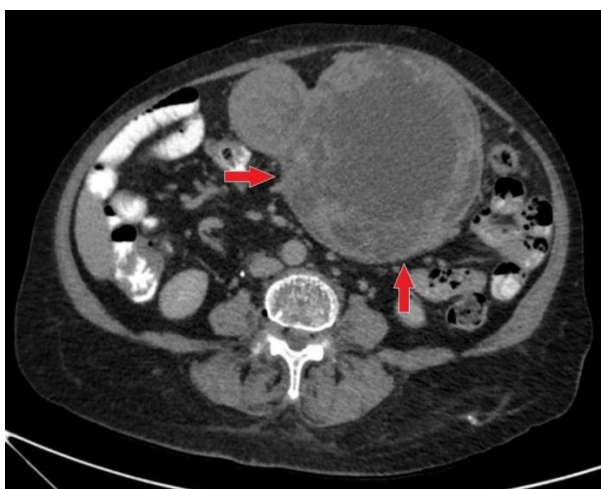


Figure 1. CECT (abdomen) finding of suggestive malignant GIST (~20x18)cm arising from stomach body (red arrows).

The patient was referred for a preoperative assessment, which included a detailed cardiac evaluation due to her age and history of hypertension. Cardiovascular function was deemed adequate for surgery. Given the size of the tumor and the risk of complications, surgical resection was planned.

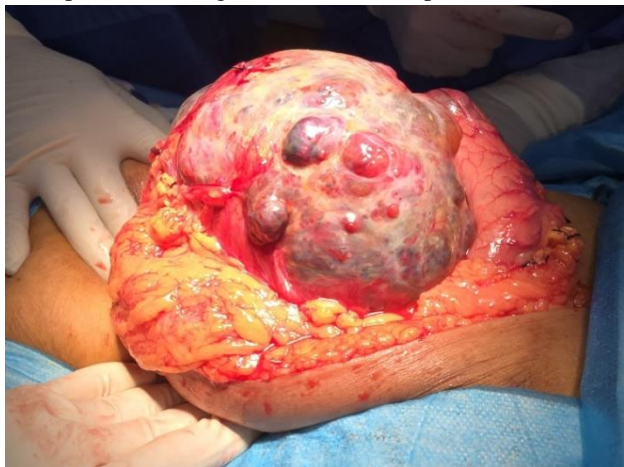

Figure 2. Intraoperative finding of gastric mass adherent with transverse colon and nearby structures.

The patient underwent an exploratory laparotomy under general anesthesia. Intraoperative findings revealed a large, globular mass with a nodular surface, measuring approximately 19 x 17 cm. The mass was located in the upper abdomen, originating from the greater curvature of the body of the stomach. It was adherent to the transverse colon, omentum, and other nearby structures (Figure 2). However, there was no evidence of ascites, liver metastases, or any other intra-abdominal abnormalities.

During surgery, the adhesions to the surrounding structures were carefully dissected (Figure 3). Excision of the mass was performed using a Covidien GIA linear stapler (60 mm, 4.8 mm), which allowed for safe removal of the tumor with clear margins (Figure 4), and a second layer of suture secured the stapled site. No intraoperative complications were encountered, and the patient's hemodynamic status remained stable throughout the procedure.

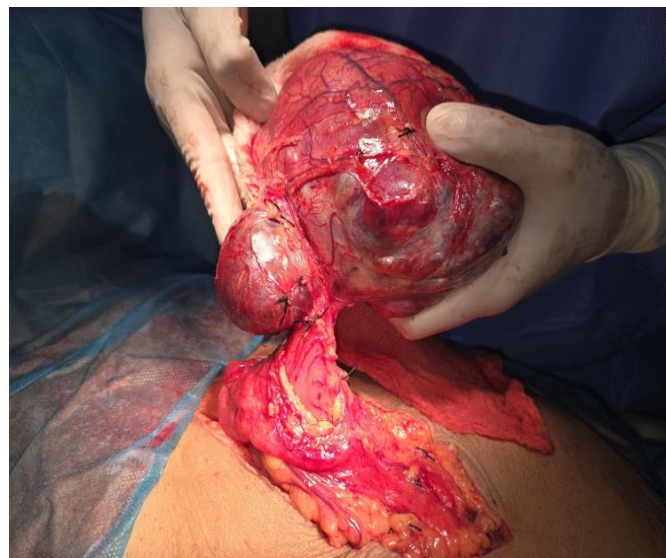

Figure 3. Intraoperative finding of gastric mass after dissection of adhesions to the surrounding structures.

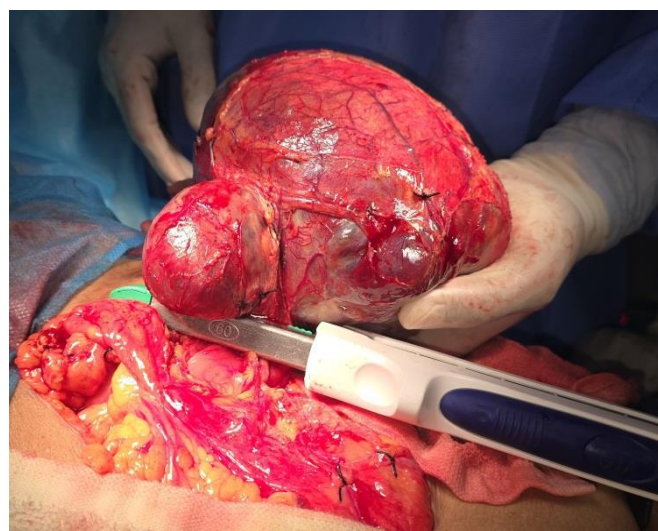


Figure 4. Intraoperative finding of gastric mass excision using a Covidien GIA linear stapler.

Asymptomatic Presentation of Large Stomach Gastrointestinal Stromal Tumour (GIST) in an Elderly Patient: A Case Report

The postoperative period was uneventful. The patient tolerated a gradual return to a normal diet and was mobilized on the first postoperative day. Pain management was achieved with routine analgesics, and no significant postoperative complications were observed. She was discharged on the seventh postoperative day in a stable condition.

Histopathological examination of the excised mass confirmed the diagnosis of an epithelioid-type gastrointestinal stromal tumor (GIST) arising from the stomach (Figure 5 and 6). The tumor had clear resection margins, and immunohistochemistry revealed positivity for CD117 (c-KIT), which is typical for GISTs. The mitotic index was low, and no evidence of necrosis or high-grade features was noted.

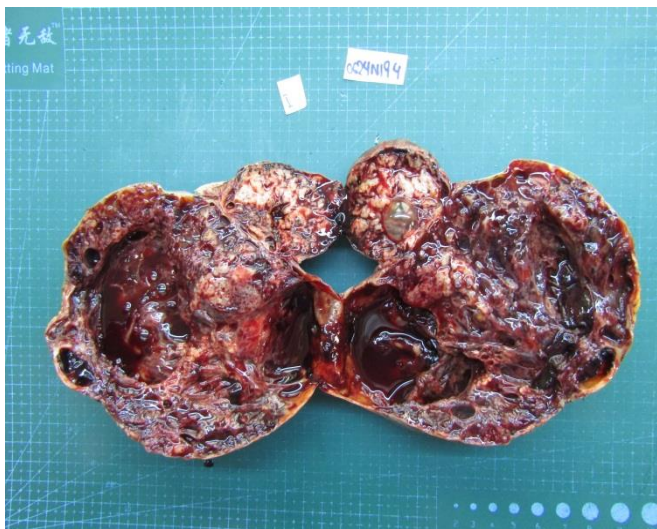


Figure 5. Gross cut section of tumour specimen with hemorrhage surface and cystic areas.

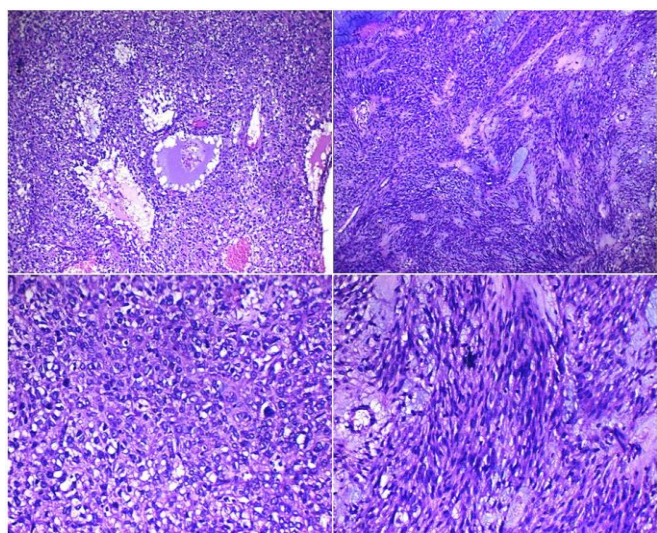


Figure 6. Histopathological finding of epithelioid-type GIST arising from the body of stomach.

Given the confirmed diagnosis of a gastric GIST, the patient was referred to an oncologist for further management. Based on the tumor size, location, and histopathological features,

adjuvant therapy with imatinib, a tyrosine kinase inhibitor, was initiated as per GIST guidelines (3). The patient was advised on long-term follow-up, including regular imaging to monitor for recurrence or metastasis.

At her three-month follow-up, the patient remained asymptomatic, with no evidence of tumor recurrence on imaging studies. Her quality of life was reported to be good, and she continued her oncological treatment.

DISCUSSION

GISTs are the most common mesenchymal tumors of the gastrointestinal tract, although they remain relatively rare compared to other gastrointestinal neoplasms. Most GISTs are sporadic and occur in patients aged 60–70 years. The clinical presentation varies depending on the tumor's size and location. Small tumors are often asymptomatic, while larger ones may cause symptoms related to mass effect, including pain, obstruction, or bleeding (2).

This case is unusual due to the patient's long-standing asymptomatic presentation despite the large size of the tumor. Most gastric GISTs present with symptoms by the time they reach a significant size, such as abdominal discomfort, gastrointestinal bleeding, or signs of obstruction. The absence of symptoms in cases of large tumors, as seen in this patient, can delay diagnosis and increase the risk of complications. Although this patient's tumor reached 20 cm in size, she remained asymptomatic for two decades. This is unusual, as tumors of this size typically exert pressure on adjacent organs, causing obstruction or other mass effects.

Large GISTs are prone to complications, even in asymptomatic patients. Some of the most significant complications include:

- **Tumor Rupture:** One of the most feared complications, as rupture can lead to life-threatening intra-abdominal hemorrhage and peritoneal dissemination of tumor cells.
- **Obstruction:** Although this patient did not experience gastric outlet or intestinal obstruction, large gastric GISTs can compress the stomach or intestines, leading to obstruction and related symptoms like vomiting, constipation, or inability to tolerate oral intake.
- **Pressure Effects:** Large tumors can displace adjacent organs, leading to discomfort, early satiety, or respiratory symptoms if the tumor compresses the diaphragm.
- **Bleeding:** GISTs, particularly those with mucosal involvement, are prone to gastrointestinal bleeding. This patient did not present with such symptoms, but it remains a concern in the management of large GISTs.

Imaging plays a crucial role in diagnosing GISTs, with CT being the preferred modality for assessing the tumor's size, origin, and relation to surrounding structures (6). In this case,

Asymptomatic Presentation of Large Stomach Gastrointestinal Stromal Tumour (GIST) in an Elderly Patient: A Case Report

both ultrasound and CT were instrumental in identifying the gastric origin of the mass and guiding the surgical approach. Surgical resection with clear margins remains the mainstay of treatment for localized GISTs (5). In this case, the tumor was successfully excised using a linear stapler, ensuring clear margins and preserving gastrointestinal function. The patient had an uneventful recovery and tolerated a normal diet soon after surgery.

In cases of large or high-risk tumors, adjuvant therapy with tyrosine kinase inhibitors (TKIs) like imatinib is recommended to reduce the risk of recurrence (3). In this case, the patient was treated according to GIST guidelines, which emphasize the importance of long-term follow-up, particularly in cases with a high risk of recurrence.

Asymptomatic GISTs, particularly those of significant size, are rare in the literature. Most reports emphasize the symptomatic presentation of GISTs, especially in larger tumors. However, a few case studies describe patients with large, asymptomatic tumors, similar to this case. In one review, approximately 10-15% of GISTs were found incidentally during imaging for unrelated conditions. The absence of symptoms in these cases is thought to result from the tumor's slow growth and lack of aggressive behavior until a critical size is reached. Additionally, asymptomatic GISTs may have a more indolent biological behavior, as suggested by the low rate of metastasis or recurrence in some cases (4). Despite the asymptomatic presentation, the size of the tumor is a significant prognostic factor. Tumors larger than 10 cm are associated with a higher risk of recurrence and metastasis, even if they initially present without symptoms. This underscores the importance of surgical resection and appropriate oncological follow-up, as was done in this case.

CONCLUSION

This case highlights the unusual presentation of a large, asymptomatic gastric GIST in an 80-year-old woman. Despite its size and potential for serious complications, the patient experienced no symptoms for two decades. Surgical resection provided definitive treatment, and oncological follow-up will ensure long-term management. This case underscores the importance of considering GISTs in the differential diagnosis of large, asymptomatic abdominal masses and the need for timely intervention to prevent

complications. Long-term follow-up is crucial for monitoring recurrence or metastasis, especially in cases of large GISTs.

ACKNOWLEDGEMENTS

I would like to thank the surgical team and the patient's family for their cooperation in this case. I wish to express my sincere thanks to Dr. Daw Naw Mu Lah Eh Min, Senior Consultant Pathologist from Top Team Laboratory in Mandalay, for her kind permission to use the gross cut photographs and histopathological slides that were crucial to this report. My appreciation also goes to "Shwe Myint Mo Advanced Laboratory" in Pyin Oo Lwin for their support. Without the contributions of all those mentioned, the successful publication of this case report would not have been possible.

CONFLICTS OF INTEREST

The authors declare no conflicts of interest.

REFERENCES

- I. DeMatteo, R.P., Lewis, J.J., Leung, D., Mudan, S.S., Woodruff, J.M. and Brennan, M.F. 2000. Two Hundred Gastrointestinal Stromal Tumors: Recurrence Patterns and Prognostic Factors for Survival. *Ann. Surg.* 2000, 231(1): 51-58.
- II. Enodien, B., Hendie, D., Müller, T., et al. 2023. Gastrointestinal Stromal Tumor (GIST): A Remarkable Case Report and Literature Review. *Cureus.* 2023, 15(3): e35931.
- III. Casali, P.G. et al. 2022. Gastrointestinal stromal tumours: ESMO-EURACAN-GENTURIS Clinical Practice Guidelines for diagnosis, treatment and follow-up. *Annals of Oncology.* 2022, 33(1): 20-33.
- IV. Oliveros, R., Pinilla, R., Sánchez, R. and Contreras, H. Gastrointestinal stromal tumors (GIST). Case series. *Rev Colomb Gastroenterol.* 2021, 36(1): 172-179.
- V. Kong, S.H. and Yang, H.K. 2013. Surgical Treatment of Gastric Gastrointestinal Stromal Tumor. *J Gastric Cancer.* 2013, 13(1): 3-18.
- VI. Hashiba, T. et al. 2004. A gastrointestinal stromal tumor in the stomach: usefulness of computed tomographic volumetry. *IGCA & JGCA.* 2004, 7: 260-265.