

Incidentally Detected Meckel's Diverticulum in an Adult, Resect or Not Resect? A Case Report

Gómez-Arciniega Karen Denis*^{1a}, Gastelum-Sarabia Jesús Rodolfo^{1b}, Zepeda-Ramírez Andrea Marisol^{1c}, Ángel-Montoya Daniel Alejandro^{1d}, Pérez-Castillo María Fátima^{1e}, Mejía-Ramírez José Luis^{1f}, Pérez-Flores Gabino^{1g}

¹Department of Surgery, Centro Médico Nacional de Occidente, Instituto Mexicano del Seguro Social, Guadalajara, Jalisco, México.

^{a)} <https://orcid.org/0009-0009-7653-5072>

^{b)} <https://orcid.org/0009-0006-5067-9420>

^{c)} <https://orcid.org/0009-0001-7103-6903>

^{d)} <https://orcid.org/0009-0002-8774-4565>

^{e)} <https://orcid.org/0009-0004-5222-1881>

^{f)} <https://orcid.org/0000-0002-3699-0187>

^{g)} <https://orcid.org/0009-0008-0932-4067>

ABSTRACT

Introduction: Meckel's diverticulum is a true diverticulum that affects 2% of the population, being the most frequent congenital anomaly of the gastrointestinal tract and occurs due to a defect in the closure of the omphalomesenteric duct. It is most frequently diagnosed in children under 10 years of age, in whom it may manifest as gastrointestinal bleeding, obstruction or perforation; however, in adults it is usually asymptomatic and found incidentally during other abdominal surgery.

Case presentation: A 43-year-old male, with acute appendicitis, underwent open appendectomy, during which the presence of a 4 x 3 cm Meckel's diverticulum was incidentally identified, so ileal resection was performed, with primary anastomosis, presenting a satisfactory postoperative evolution.

Conclusion: The treatment of symptomatic Meckel's diverticulum is undoubtedly resection; however. The literature does not define whether a diverticulum found incidentally should be resected or not, especially in adults, in whom the presence of risk factors should be assessed to determine whether resection should be performed.

KEYWORDS: Meckel's diverticulum, preventive resection, congenital, diverticulectomy, appendectomy.

ARTICLE DETAILS

Published On:
21 August 2024

Available on:
<https://ijmscr.org/>

I. INTRODUCTION

Meckel's diverticulum is the most common congenital anomaly of the small intestine [1]. It results from incomplete obliteration of the vitelline duct, was described by Johan Friederich Meckel in 1809. It is rare and often clinically silent [2].

Meckel's diverticulum contains all the layers of the intestinal wall, so by definition it is a true diverticulum [3]. It is located at the antimesenteric border, at a distance of approximately 52.4 cm with a range of 7 to 100 cm from the ileocecal valve, its length is usually 1.58 centimeters, and its diameter is 3 centimeters [3].

Meckel's diverticulum is a rare entity that affects 1 to 4% of people and is usually discovered mostly during childhood [1].

Treatment of symptomatic Meckel's diverticulum is resection [1]. When it is discovered incidentally whether to resect it or leave it in situ is currently a controversial issue [4].

We report the case of a male patient with acute appendicitis and an incidental finding of a Meckel's diverticulum in which resection was performed. The work has been reported in line with the SCARE

Incidentally Detected Meckel's Diverticulum in an Adult, Resect or Not Resect? A Case Report

II. CASE PRESENTATION

Male patient, 43 years old, with no history of chronic degenerative diseases or previous surgeries. He presented to the emergency department because he started 24 hours before admission with periumbilical pain that later radiated to the right iliac fossa and added anorexia, nausea and vomiting on 3 occasions.

On physical examination, the patient was febrile with 38.5°C, abdominal distension, generalized abdominal pain predominantly in the right iliac fossa with positive McBurney, voluntary muscle resistance, positive Blumberg, positive psoas, positive obturator, positive Heel tap sign.

Laboratory investigations showed leukocytosis and neutrophilia (Table 1). Simple abdominopelvic CT scan showing an apparent lithium in the upper pole of the right kidney, with no alterations suggestive of acute appendicitis. (Figure. I)

Table 1: Laboratory results.

Test	Result	Unit	Reference value
Hemoglobin	17.6	g/dl	12.00-17.80
WBC	10.6	10 ³ /μL	4.00-10.00
Neu	80	%	40-60
PLT	339,000	10 ³ /μL	130-400
Glucose	118	mg/dL	74.00-106.00

WBC: white blood cell; Neu: Neutrophil., PLT: platelets.

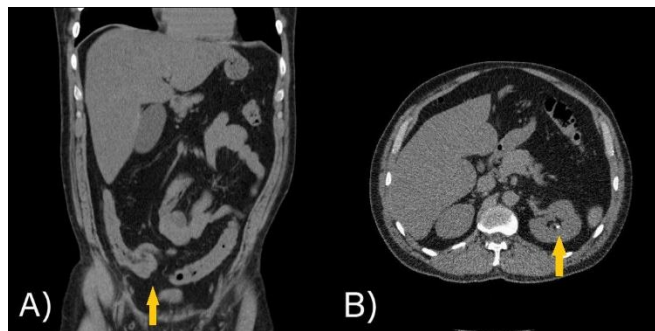


Figure I. Abdominal CT scan. A) Coronal section, the yellow arrow shows absence of date of acute appendicitis. B) Axial section, the yellow arrow shows lithoid in left renal topography.

A score of 9 on the modified Alvarado scale and a score of 11.5 on the RIPASA scale were obtained, suggestive of a high probability of acute appendicitis, so emergency surgery by open appendectomy was decided.

Surgical intervention was performed and the following findings were obtained: Abdominal cavity without presence of free liquid, cecal appendix edematous, congestive, stage II appendicitis with dimensions of 10 x 2 x 1 cm, with base of cecum respected, so appendectomy was performed with Pouchet technique, when examining the ileal loops was evidenced the presence of a Meckel's diverticulum with

dimensions of 4 x 3 cm to 80 cm proximal to the ileocecal valve in the antimesenteric edge (Fig. 2), Therefore, a segment of ileum was resected approximately 5 cm (Fig. 3), and a manual end-to-end anastomosis was performed in two planes, first plane with Polyglactine 910 suture 000, continuous surge, second plane with Polyglactine 910 suture 000 Connell-Mayo stitches, pneumatic test was performed without evidence of leaks, mesenteric gap was closed with Polyglactine 910 suture 000 Cushing stitches.

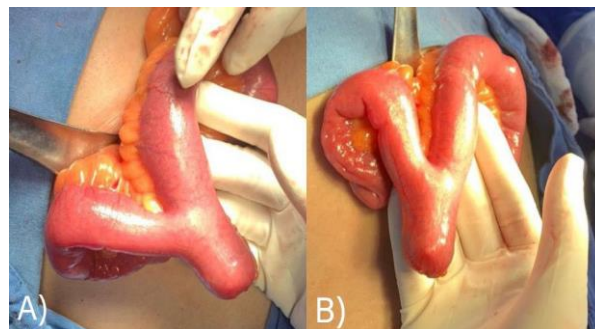


Figure II. Meckel's diverticulum. Photographs A) and B) showing the Meckel's diverticulum with wide base, without inflammation data.

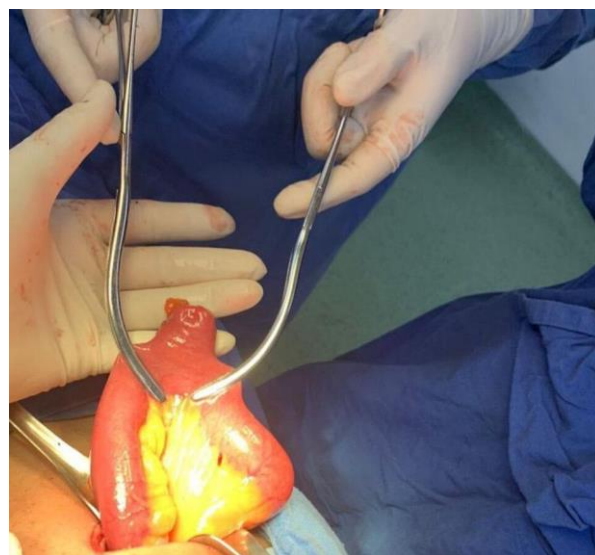


Figure III. Ileal resection at the site of Meckel's diverticulum.

Patient with satisfactory postoperative evolution, enteral diet was restarted at 48 hours, with no evidence of intestinal leakage or other complications, he was discharged home at 72 hours.

III. DISCUSSION

The congenital anomaly of the digestive tract is Meckel's diverticulum [4,5]. It is present in up to 2% of the population, with a 3:2 prevalence ratio between men and women [1,5].

The condition results from incomplete obliteration of the omphalomesenteric (vitelline) duct, located at the antimesenteric border of the distal ileum in the axis and continuity of the superior mesenteric artery, within the first

Incidentally Detected Meckel's Diverticulum in an Adult, Resect or Not Resect? A Case Report

100 cm of the ileocecal valve in an adult [5]. Its wall is composed of heterotopic mucosa, up to 60% of which is usually gastric mucosa, followed by pancreatic tissue (16%) [5].

The characteristics of Meckel's diverticulum yield the "rule of 2": present in 2% of people, it is located 2 feet from the ileocecal valve, measures 2 inches in length, contains 2 types of mucosae, and its presentation usually occurs before the age of 2 years [1].

Meckel's diverticulum is usually asymptomatic, and only occasionally can present with complications throughout any age from infants to the elderly, but mainly affects children [4].

More than 50% of patients who develop complications are younger than 10 years, being highest in early childhood (<2 years) the lifetime incidence rate of complications is estimated at 4%, the risk of complications decreases with age, being as low as 1% in patients in their 40s and virtually absent at age 70 [4,5].

In children, when symptomatic, it manifests as mechanical intestinal obstruction, gastrointestinal bleeding and diverticulitis [4].

In up to 70-80% of adults its finding is accidental when performing other abdominal surgery. In adults the symptoms include lower gastrointestinal bleeding in 8 to 63%. The cause of bleeding is ectopic gastric mucosa within the diverticulum leading to peptic ulcer formation. Mechanical obstruction of the gastrointestinal tract occurring in 14 to 40% of symptomatic patients, the obstruction may also be caused by incarceration of the diverticulum within an umbilical or inguinal hernia [4]. Another cause of obstruction or strangulation is the persistence of the omphalomesenteric ligament that connects the umbilicus to the diverticulum; this persistence occurs in 15% of Meckel's diverticula [1].

Diverticulitis is one of the most common complications in adults and occurs in 30 to 58% of patients who develop symptoms [4].

Perforation is a very rare complication, caused by fecaliths formed within the diverticulum causing ulceration or by a foreign body trapped within the lumen [4]. Also, the presence of an ectopic gastric mucosa can lead to the formation of neoplasms, such as carcinoid tumors, GIST, adenocarcinomas and sarcomas [4].

The diagnosis of Meckel's diverticulum represents a challenge, due to its asymptomatic course in most cases. Several imaging studies are used for diagnosis (ultrasound, computed tomography angiography, capsule endoscopy [6]. However, the diagnostic method of choice is radionuclide imaging with technetium-99m pertechnetate scintigraphy, because most diverticula contain heterotopic gastric tissue [7]. The sensitivity of this study in children is 80 to 90% and its specificity is 95 to 98%, in adults the sensitivity is 62.5%, it is suspected that this is because the presence of ectopic gastric tissue is less common in symptomatic ageing patients [6].

Angiography may reveal a vitelline artery branching from the superior mesenteric artery, which is pathognomonic of Meckel's diverticulum [8].

The treatment of symptomatic Meckel's diverticulum is resection, the optimal surgical management varies according to the appearance of the diverticulum and the presentation. In the case of diverticula whose base is small and not inflamed or perforated, simple diverticulectomy is recommended. On the other hand, segmental resection of the ileum containing the diverticulum is recommended if the base is wide, inflamed, perforated, contains a bleeding ulcer, or if a diverticulectomy would result in significant luminal narrowing [9]. Resection can be accomplished by a laparoscopic or open technique [1,10].

Some authors recommend surgical treatment with resection and anastomosis instead of resecting the diverticulum alone by wedge or tangential resection, to reduce the risk of leaving residual heterotopic mucosa [1].

On the other hand, the treatment of Meckel's diverticulum detected incidentally during an abdominal procedure is still controversial, since there is no evidence in the literature to support either resection or leaving it in situ [2]. It is reasonable that decision making should be based on the presence of risk factors for developing future complications [10].

The most recent literature defines a series of characteristics and clinical situations that opt for "preventive" excision of an accidentally found Meckel's diverticulum, which are: Age less than 50 years, male sex, diverticulum length greater than 2 cm, macroscopic features of ectopic mucosa, narrow neck diverticulum, connection of the upper part of the diverticulum to the umbilicus with a band of connective tissue. [4,6,11].

Park J & cols recommend removal of all incidental diverticula that meet any of the first 4 criteria listed above [11].

In the case of our patient, it was an incidental finding during an appendectomy, the patient was younger than 50 years old, male and his Meckel's diverticulum was longer than 2 cm, therefore he met 3 of the risk factors mentioned in the literature to consider its removal, Therefore, it was decided to perform an ileal resection and primary anastomosis instead of a diverticulectomy or wedge resection due to the presence of a wide-based diverticulum, the patient evolved favorably, without the presence of post-surgical complications.

CONCLUSIONS

Meckel's diverticulum is the most common gastrointestinal congenital anomaly. It is a true diverticulum that occurs in the distal ileum because of inadequate obliteration of the omphalomesenteric duct. It is usually asymptomatic, especially in adults, making it a diagnostic challenge.

The treatment of symptomatic Meckel's diverticulum is undoubtedly resection, however there is

Incidentally Detected Meckel's Diverticulum in an Adult, Resect or Not Resect? A Case Report

controversy as to whether resection of a non-symptomatic Meckel's diverticulum found incidentally should be performed, especially in adults, the current trend is towards removal of those diverticula with potential risk of subsequent complications, however the proposed criteria vary among the available studies.

CONFLICTS OF INTEREST:

The authors declare that they have no known competing financial interests or personal relationships that could have appeared to influence the work reported in this paper.

REFERENCES

- I. Yorkgitis BK, Devecki K. Managing Meckel diverticulum. *JAAPA* 2020;33:30-2. <https://doi.org/10.1097/01.jaa.0000697244.35582.cb>
- II. Zani A, Eaton S, Rees CM, Pierro A. Incidentally detected Meckel diverticulum. *Annals Of Surgery* 2008;247:276-81. <https://doi.org/10.1097/sla.0b013e31815aaaf8>
- III. Zanchetta M, Inversini D, Pappalardo V, Grappolini N, Morabito M, Gianazza S, et al. Meckel's diverticulum causing ileal volvulus and peritonitis after a recent appendectomy: a case report and literature review—We should likely resect an incidental MD. *Life* 2023;13:1996. <https://doi.org/10.3390/life13101996>.
- IV. Zyluk A. Proceeding with incidentally discovered, unchanged Meckel's diverticulum – a review. *Polish Journal Of Surgery* 2019;91:1-5. <https://doi.org/10.5604/01.3001.0013.3400>.
- V. Parvanescu A, Bruzzi M, Voron T, Tilly C, Zinzindohoué F, Chevallier J-M, et al. Complicated Meckel's diverticulum. *Medicine* 2018;97:e12457. <https://doi.org/10.1097/md.00000000000012457>.
- VI. Lindeman R-J, Søreide K. The many faces of Meckel's diverticulum: update on management in incidental and symptomatic patients. *Current Gastroenterology Reports* 2020;22. <https://doi.org/10.1007/s11894-019-0742-1>.
- VII. Bani-Hani KE, Shatnawi NJ. Meckel's Diverticulum: Comparison of Incidental and Symptomatic Cases. *World Journal Of Surgery* 2004;28:917-20. <https://doi.org/10.1007/s00268-004-7512-3>.
- VIII. Hansen C-C, Søreide K. Systematic review of epidemiology, presentation, and management of Meckel's diverticulum in the 21st century. *Medicine* 2018;97:e12154. <https://doi.org/10.1097/md.00000000000012154>.
- IX. Fusco JC, Achey MA, Upperman JS. Meckel's diverticulum: Evaluation and management. *Seminars In Pediatric Surgery* 2022;31:151142. <https://doi.org/10.1016/j.sempedsurg.2022.151142>.
- X. Blouhos K, Boulas KA, Tsalis K, Baretas N, Paraskeva A, Kariotis I, et al. Meckel's Diverticulum in Adults: Surgical Concerns. *Frontiers In Surgery* 2018;5. <https://doi.org/10.3389/fsurg.2018.00055>.
- XI. Park JJ, Wolff BG, Tollefson MK, Walsh EE, Larson DR. Meckel diverticulum. *Annals Of Surgery* 2005;241:529-33. <https://doi.org/10.1097/01.sla.0000154270.14308.5f>.