

## **Case Report: Giant Zenker Diverticulum**

**Jaime Cruz González<sup>1</sup>, Alexis Rafael Juarez Leon<sup>2</sup>, Victor Mario Martinez Bravo<sup>2</sup>, Monica Maria Ramirez Guerrero<sup>3</sup>, Saul Raciél Cárdenas Martínez<sup>4</sup>, Casandra Lizeth Castro Zacarias<sup>5</sup>, Isaac Omar Serna Delgado<sup>6</sup>, Luis Eduardo Paz Malagón<sup>7</sup>**

<sup>1</sup>Universidad de Monterrey

<sup>2</sup>Hospital Regional de alta especialidad ISSSTE Veracruz

<sup>3</sup>Universidad del Noreste, Tamaulipas

<sup>4</sup>Instituto Politécnico Nacional CICS UMA

<sup>5</sup>Universidad Nacional Autónoma de México

<sup>6</sup>Hospital General de Pabellón de Arteaga, Aguascalientes

<sup>7</sup>Hospital San José, Zamora, Michoacán.

### **ABSTRACT**

Giant Zenker diverticulum represents a challenging clinical entity in the field of otolaryngology. We present an interesting case report and a bibliographic review to provide a comprehensive overview of this condition. The article delves into this condition, including its definition, risk factors, complications, and management strategies. The discussion section highlights emerging approaches and future directions in the management of giant Zenker diverticulum. In conclusion, the importance of evidence-based practices in addressing this complex condition is emphasized.

**KEYWORDS:** Giant Zenker Diverticulum, Hypopharyngeal Diverticulum, Zenker's Diverticulum, Pharyngeal Pouch, Dysphagia.

### **ARTICLE DETAILS**

**Published On:**  
**06 November 2023**

**Available on:**  
<https://ijmscr.org/>

### **INTRODUCTION**

Giant Zenker diverticulum is a rare but clinically significant disorder that affects the pharynx, leading to the formation of a pouch or outpouching in the hypopharyngeal region. While Zenker diverticulum itself is relatively uncommon, giant Zenker diverticulum represents an even more infrequent variant. Understanding the epidemiology of this condition provides valuable insights into its occurrence and impact on patient populations.<sup>1</sup>

The clinical transcendence of giant Zenker diverticulum extends beyond its rarity. It touches upon various aspects of patient care, healthcare costs, and the advancement of surgical techniques. The recognition and effective management of giant Zenker diverticulum are essential not only for patient well-being but also for minimizing healthcare expenditures and guiding the evolution of surgical practice in the field of otolaryngology.<sup>2</sup>

### **CASE REPORT**

74-year-old male who started in October 2023 during previous hospitalization for pancreatitis of undetermined origin with regurgitation of food, so gastroenterology

performed upper endoscopy, which reported KODSI IV esophageal candidiasis and esophageal stenosis + probable esophageal diverticulum, so The gastrostomy tube is placed in another unit to be able to feed and it is sent for handling by us.

12/20/2022: hemoglobin 10.7, hematocrit 27.5, platelets 257 thousand, tp 10.9, inr 0.9, ttp 31.1, glucose 85, urea 21.4, creatinine 0.8, group o +

12/15/2022 ekg: sinus bradycardia rhythm hr 46 bpm, with right bundle branch block, ekg without signs of ischemia, injury or necrosis

Panendoscopy 10/07/2022: esophagus from the proximal third covered with circumferential plates that leave areas of mucosal denudation when removed, at 25 cm the esophagus ends in the blind cul-de-sac. No esophageal lumen is visualized. Diagnostic impression; kodsiv esophageal candidiasis / esophageal stricture + probable esophageal diverticulum.

Esophagogastroduodenal series 11/22/2022: Esophagus with tortuous appearance, great dilation is observed at the level of the proximal third (cervical), saccular appearance, with filling as contrast medium passes, approximately 7.1 x 9.9 cm. Rest

## Case Report: Giant Zenker Diverticulum

of the esophagus with irregular walls and thickened folds, with no filling defects seen along its path. There is no difficulty in passing the contrast through the lower sphincter (cardia), which is located inferior to the diaphragm. In the stress phase, no signs of a hiatal hernia were observed. No gastroesophageal reflux was demonstrated during the dynamic stress study. Stomach well located, with irregular contours, not distended, without lesions in the mucosa or folds, greater and lesser curvature and gastric antrum are of normal configuration, without filling defects

Histopathology report 10/07/2022: ACUTE ABSCEDEDADA ESOPHAGITIS + ESOPHAGEAL CANDIDIASIS

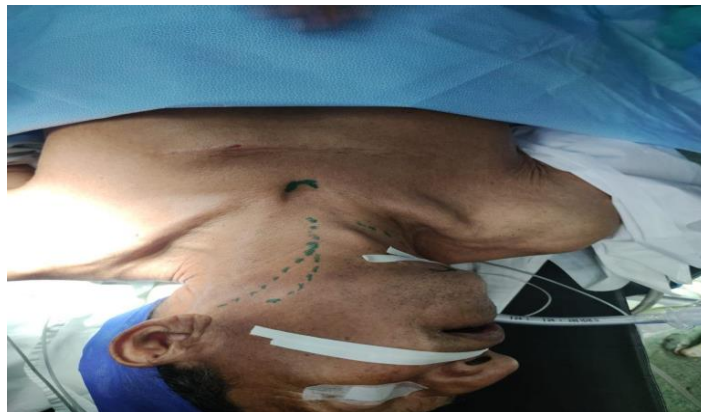

Figure 1. Preoperative marks.

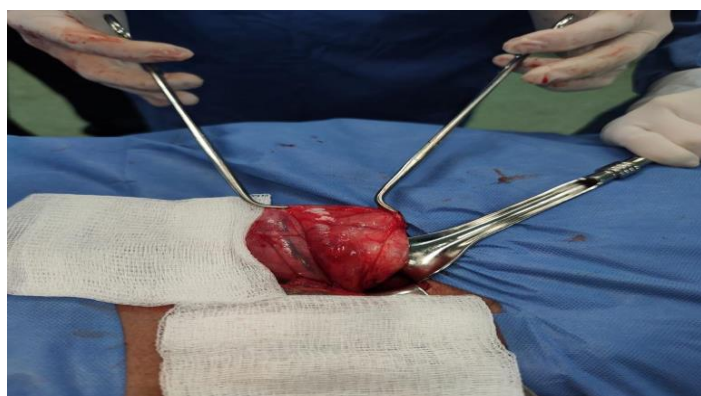


Figure 2. Lateral view of diverticulum.

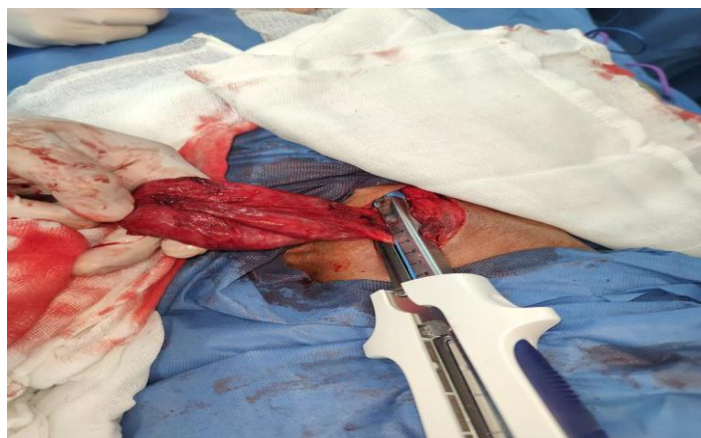

Figure 3. Diverticulum excision

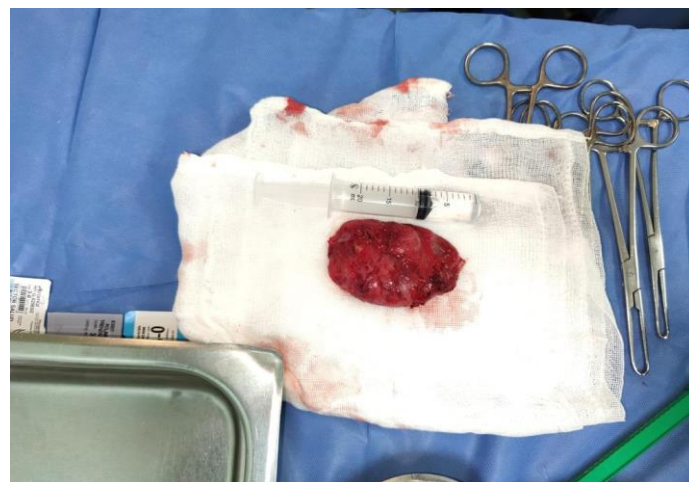

Figure 4. Surgical piece

## DISCUSSION

### Definition:

Giant Zenker diverticulum, a variant of Zenker diverticulum, is characterized by the presence of a large, sac-like outpouching in the hypopharynx. This outpouching typically occurs posterior to the cricopharyngeal muscle, resulting from increased pressure in the hypopharynx, and is lined with mucosa. The term "giant" is often applied when the diverticulum reaches a certain size threshold, typically greater than 4 cm in diameter. This condition is associated with symptoms such as dysphagia, regurgitation, halitosis, and aspiration.<sup>2, 3, 4</sup>

### Risk Factors:

**Age:** Giant Zenker diverticulum is more commonly observed in older individuals, especially those over 60 years of age. Age-related changes in the pharyngeal muscles and anatomy may play a role.<sup>5</sup>

**Chronic Hypopharyngeal Stasis:** Chronic stasis of food and secretions in the hypopharynx, often related to cricopharyngeal dysfunction or motility disorders, can increase the risk of diverticulum formation.<sup>6</sup>

**Smoking and Alcohol Use:** These lifestyle factors have been associated with an increased risk of Zenker diverticulum, and they may also contribute to the development of giant Zenker diverticulum.<sup>5</sup>

**Genetic Predisposition:** While not well-defined, there may be genetic factors that influence an individual's susceptibility to developing giant Zenker diverticulum.<sup>5</sup>

### Complications:

Understanding the complications associated with giant Zenker diverticulum is crucial for a comprehensive approach to its management:

**Dysphagia:** Dysphagia is a hallmark symptom, and it may range from mild to severe, significantly impacting a patient's quality of life.<sup>7</sup>

**Regurgitation:** The presence of a diverticulum can lead to regurgitation of undigested food, which can be distressing and potentially lead to aspiration.<sup>5</sup>

**Halitosis:** Foul-smelling breath, or halitosis, is a common complaint in patients with giant Zenker diverticulum, often

## Case Report: Giant Zenker Diverticulum

due to the stagnation of food particles and secretions in the pouch.<sup>6</sup>

**Aspiration Pneumonia:** In severe cases, aspiration of retained material from the diverticulum can lead to recurrent episodes of aspiration pneumonia, a potentially life-threatening complication.<sup>8</sup>

**Management:**

The management of giant Zenker diverticulum involves a systematic approach:

**Diagnostic Evaluation:** A thorough diagnostic evaluation, including barium swallow studies, upper endoscopy, and manometry, is crucial to confirm the diagnosis and assess the size and characteristics of the diverticulum.<sup>7</sup>

**Conservative Measures:** In some cases, conservative measures such as dietary modifications and swallowing therapy may be considered, particularly for patients with mild symptoms.<sup>7</sup>

**Surgical Intervention:** For patients with significant symptoms or complications, surgical intervention is often necessary. Surgical options include open or endoscopic diverticulectomy, myotomy, and cricopharyngeal dilation.<sup>9</sup>

**Endoscopic Techniques:** Endoscopic approaches have gained popularity for the treatment of giant Zenker diverticulum, offering reduced invasiveness and shorter recovery times.<sup>10</sup>

**Postoperative Care:** Postoperative care is critical to ensure a successful outcome. Patients require close monitoring and may need nutritional support in the immediate postoperative period.<sup>1</sup>

**Emerging Approaches:**

Emerging approaches in the management of giant Zenker diverticulum offer potential improvements in patient care:

**Endoscopic Techniques:** Endoscopic diverticulotomy with or without diverticulectomy has become a favored approach due to its minimally invasive nature and reduced morbidity. These techniques utilize flexible endoscopes and special instruments to create a passage between the esophagus and the diverticulum, relieving symptoms.<sup>10</sup>

**Enhanced Quality of Life:** Emerging approaches and future directions hold the potential to significantly enhance the quality of life for patients with giant Zenker diverticulum. Minimally invasive techniques, personalized treatment, and biologic therapies may lead to improved symptom control and reduced complications.<sup>11</sup>

In this particular case, an 8x12 cm cricopharyngeal diverticulum was found with a 4 cm base that elongated to the entrance of the mediastinum. Careful dissection of the same and traction of the sac to the cervical surgical area was performed without complications. The myotomy was performed with monopolar energy and blunt dissection of 6 cm, it is performed after canalization with a 36fr bougie, stapling at the base with an open 3.5mm blue cartridge and the piece is extracted without complications.

At the 6-month review and physical examination, the patient had adequate healing, with adequate post-surgical evolution.

No dysphagia, no regurgitation, no weight loss. Gastrostomy tube site already healed, tolerating oral diet normally.

## CONCLUSION

Giant Zenker diverticulum is a rare but clinically significant condition with a unique theoretical framework, risk factors, and complications. Emerging approaches and future directions offer hope for improved patient outcomes, with minimally invasive techniques and personalized treatment plans playing a pivotal role. As the field continues to evolve, evidence-based approaches will be essential in addressing this complex clinical problem.

## REFERENCES

- I. Marrero, F. J., & Achkar, E. (2012). Esophageal diverticula. *The Esophagus*, 351-366.
- II. Ferreira, L. E. V. V. C., Simmons, D. T., & Baron, T. H. (2008). Zenker's diverticula: pathophysiology, clinical presentation, and flexible endoscopic management. *Diseases of the Esophagus*, 21(1), 1-8.
- III. Nuño-Guzmán, C. M., García-Carrasco, D., Haro, M., Arróniz-Jáuregui, J., Corona, J. L., & Salcido, M. (2014). Zenker's Diverticulum: diagnostic approach and surgical management. *Case reports in gastroenterology*, 8(3), 346-352.
- IV. Suman, S. K., Kumar, A., Kumar, V., Prasad, U., & Singh, M. (2016). Giant Zenker's diverticula. *Journal of Evolution of Medical and Dental Sciences*, 5(33), 1855-1858.
- V. Law, R., Katzka, D. A., & Baron, T. H. (2014). Zenker's diverticulum. *Clinical Gastroenterology and Hepatology*, 12(11), 1773-1782.
- VI. Tolep, K., Getch, C. L., & Criner, G. J. (1996). Swallowing dysfunction in patients receiving prolonged mechanical ventilation. *Chest*, 109(1), 167-172.
- VII. Yuan, Y., Zhao, Y. F., Hu, Y., & Chen, L. Q. (2013). Surgical treatment of Zenker's diverticulum. *Digestive Surgery*, 30(3), 207-218.
- VIII. Sue Eisenstadt, E. (2010). Dysphagia and aspiration pneumonia in older adults. *Journal of the American academy of Nurse Practitioners*, 22(1), 17-22.
- IX. Veenker, E., & Cohen, J. I. (2003). Current trends in management of Zenker diverticulum. *Current Opinion in Otolaryngology & Head and Neck Surgery*, 11(3), 160-165.
- X. Case, D. J., & Baron, T. H. (2010, August). Flexible endoscopic management of Zenker diverticulum: the Mayo Clinic experience. In *Mayo Clinic Proceedings* (Vol. 85, No. 8, pp. 719-722). Elsevier.
- XI. Sideris, L., Chen, L. Q., Ferraro, P., & Duranceau, A. C. (1999, October). The treatment of Zenker's diverticula: a review. In *Seminars in Thoracic and Cardiovascular Surgery* (Vol. 11, No. 4, pp. 337-351). WB Saunders.